

# NCCN Guidelines® Insights

## Neuroendocrine and Adrenal Tumors, Version 2.2018

### Featured Updates to the NCCN Guidelines

Manisha H. Shah, MD<sup>1,\*</sup>; Whitney S. Goldner, MD<sup>2,\*</sup>; Thorvardur R. Halfdanarson, MD<sup>3,\*</sup>; Emily Bergsland, MD<sup>4,\*</sup>; Jordan D. Berlin, MD<sup>5,\*</sup>; Daniel Halperin, MD<sup>6,\*</sup>; Jennifer Chan, MD<sup>7,\*</sup>; Matthew H. Kulke, MD<sup>7</sup>; Al B. Benson III, MD<sup>8</sup>; Lawrence S. Blaszkowsky, MD<sup>9</sup>; Jennifer Eads, MD<sup>10</sup>; Paul F. Engstrom, MD<sup>11</sup>; Paul Fanta, MD<sup>12</sup>; Thomas Giordano, MD, PhD<sup>13</sup>; Jin He, MD, PhD<sup>14</sup>; Martin J. Heslin, MD<sup>15</sup>; Gregory P. Kalemkerian, MD<sup>13</sup>; Fouad Kandeel, MD, PhD<sup>16</sup>; Sajid A. Khan, MD<sup>17</sup>; Wajih Zaheer Kidwai, MD<sup>17</sup>; Pamela L. Kunz, MD<sup>18</sup>; Boris W. Kuvshinov II, MD, MBA<sup>19</sup>; Christopher Lieu, MD<sup>20</sup>; Venu G. Pillarisetty, MD<sup>21</sup>; Leonard Saltz, MD<sup>22</sup>; Julie Ann Sosa, MD<sup>23</sup>; Jonathan R. Strosberg, MD<sup>24</sup>; Craig A. Sussman, MD<sup>5</sup>; Nikolaos A. Trikalinos, MD<sup>25</sup>; Nataliya A. Uboha, MD, PhD<sup>26</sup>; Jonathan Whisenant, MD<sup>27</sup>; Terence Wong, MD<sup>23</sup>; James C. Yao, MD<sup>6</sup>; Jennifer L. Burns<sup>28</sup>; Ndiya Ogba, PhD<sup>28</sup>; and Griselda Zuccarino-Catania, PhD<sup>28</sup>

#### Abstract

The NCCN Guidelines for Neuroendocrine and Adrenal Tumors provide recommendations for the management of adult patients with neuroendocrine tumors (NETs), adrenal gland tumors, pheochromocytomas, and paragangliomas. Management of NETs relies heavily on the site of the primary NET. These NCCN Guidelines Insights summarize the management options and the 2018 updates to the guidelines for locoregional advanced disease, and/or distant metastasis originating from gastrointestinal tract, bronchopulmonary, and thymus primary NETs.

*J Natl Compr Canc Netw* 2018;16(6):693–702  
doi: 10.6004/jnccn.2018.0056

<sup>1</sup>The Ohio State University Comprehensive Cancer Center - James Cancer Hospital and Solove Research Institute; <sup>2</sup>Fred & Pamela Buffett Cancer Center; <sup>3</sup>Mayo Clinic Cancer Center; <sup>4</sup>UCSF Helen Diller Family Comprehensive Cancer Center; <sup>5</sup>Vanderbilt-Ingram Cancer Center; <sup>6</sup>The University of Texas MD Anderson Cancer Center; <sup>7</sup>Dana-Farber/Brigham and Women's Cancer Center; <sup>8</sup>Robert H. Lurie Comprehensive Cancer Center of Northwestern University; <sup>9</sup>Massachusetts General Hospital Cancer Center; <sup>10</sup>Case Comprehensive Cancer Center/University Hospitals Seidman Cancer Center and Cleveland Clinic Taussig Cancer Institute; <sup>11</sup>Fox Chase Cancer Center; <sup>12</sup>UC San Diego Moores Cancer Center; <sup>13</sup>University of Michigan Rogel Cancer Center; <sup>14</sup>The Sidney Kimmel Comprehensive Cancer Center at Johns Hopkins; <sup>15</sup>University of Alabama at Birmingham Comprehensive Cancer Center; <sup>16</sup>City of Hope Comprehensive Cancer Center; <sup>17</sup>Yale Cancer Center/Smilow Cancer Hospital; <sup>18</sup>Stanford Cancer Institute; <sup>19</sup>Roswell Park Comprehensive Cancer Center; <sup>20</sup>University of Colorado Cancer Center; <sup>21</sup>University of Washington/Seattle Cancer Care Alliance; <sup>22</sup>Memorial Sloan Kettering Cancer Center; <sup>23</sup>Duke Cancer Institute; <sup>24</sup>Moffitt Cancer Center; <sup>25</sup>Siteman Cancer Center at Barnes-Jewish Hospital and Washington University School of Medicine; <sup>26</sup>University of Wisconsin Carbone Cancer Center; <sup>27</sup>Huntsman Cancer Institute at the University of Utah; and <sup>28</sup>National Comprehensive Cancer Network.

\*Provided content development and/or authorship assistance.

#### Please Note

The NCCN Clinical Practice Guidelines in Oncology (NCCN Guidelines®) are a statement of consensus of the authors regarding their views of currently accepted approaches to treatment. **The NCCN Guidelines® Insights highlight important changes to the NCCN Guidelines® recommendations from previous versions. Colored markings in the algorithm show changes and the discussion aims to further the understanding of these changes by summarizing salient portions of the NCCN Guideline Panel discussion, including the literature reviewed.**

These NCCN Guidelines Insights do not represent the full NCCN Guidelines; further, the National Comprehensive Cancer Network® (NCCN®) makes no representation or warranties of any kind regarding the content, use, or application of the NCCN Guidelines and NCCN Guidelines Insights and disclaims any responsibility for their applications or use in any way.

**The full and most current version of these NCCN Guidelines are available at [NCCN.org](http://NCCN.org).**

© National Comprehensive Cancer Network, Inc. 2018, All rights reserved. The NCCN Guidelines and the illustrations herein may not be reproduced in any form without the express written permission of NCCN.

## Neuroendocrine and Adrenal Tumors, Version 2.2018

**NCCN: Continuing Education**

**Target Audience:** This activity is designed to meet the educational needs of physicians, nurses, and pharmacists involved in the management of patients with cancer.

**Accreditation Statement NCCN**

**Physicians:** National Comprehensive Cancer Network is accredited by the Accreditation Council for Continuing Medical Education (ACCME) to provide continuing medical education for physicians.

NCCN designates this journal-based CE activity for a maximum of 1.0 *AMA PRA Category 1 Credit™*. Physicians should claim only the credit commensurate with the extent of their participation in the activity.

**Nurses:** National Comprehensive Cancer Network is accredited as a provider of continuing nursing education by the American Nurses Credentialing Center's Commission on Accreditation.

NCCN designates this educational activity for a maximum of 1.0 contact hour.



**Pharmacists:** National Comprehensive Cancer Network is accredited by the Accreditation Council for Pharmacy Education as a provider of continuing pharmacy education.

NCCN designates this knowledge-based continuing education activity for 1.0 contact hour (0.1 CEUs) of continuing education credit. UAN: 0836-0000-18-006-H01-P

All clinicians completing this activity will be issued a certificate of participation. To participate in this journal CE activity: 1) review the educational content; 2) take the posttest with a 66% minimum passing score and complete the evaluation at <http://education.nccn.org/node/83111>; and 3) view/print certificate.

**Pharmacists:** You must complete the posttest and evaluation within 30 days of the activity. Continuing pharmacy education credit is reported to the CPE Monitor once you have completed the posttest and evaluation and claimed your credits. Before completing these requirements, be sure your NCCN profile has been updated with your NAPB e-profile ID and date of birth. Your credit cannot be reported without this information. If you have any questions, please e-mail [education@nccn.org](mailto:education@nccn.org).

Release date: June 10, 2018; Expiration date: June 10, 2019

**Learning Objectives:**

Upon completion of this activity, participants will be able to:

- Integrate into professional practice the updates to the NCCN Guidelines for Neuroendocrine and Adrenal Tumors
- Describe the rationale behind the decision-making process for developing the NCCN Guidelines for Neuroendocrine and Adrenal Tumors

**Disclosure of Relevant Financial Relationships**

The NCCN staff listed below discloses no relevant financial relationships:

Kerrin M. Rosenthal, MA; Kimberly Callan, MS; Genevieve Emberger Hartzman, MA; Erin Hesler; Kristina M. Gregory, RN, MSN, OCN; Rashmi Kumar, PhD; Karen Kanefield; and Kathy Smith.

**Individuals Who Provided Content Development and/or Authorship Assistance:**

**Manisha H. Shah, MD**, Panel Chair, has disclosed that she has received grant/research support from Eisai Inc., Loxo Oncology, Inc., and Merck & Co., Inc., and that she has served on the advisory board of Loxo Oncology, Inc. and Novartis Pharmaceuticals Corporation.

**Whitney S. Goldner, MD**, Panel Vice Chair, has disclosed that she has received other financial benefit from AstraZeneca Pharmaceuticals LP, Eisai Inc., and Roche Laboratories, Inc.

**Thorvardur R. Halfdanarson, MD**, Panel Member, has disclosed that he has received grant/research support from Agios, Inc., Ipsen, and ArQule, Inc.

**Emily Bergsland, MD**, Panel Member, has disclosed that she has received grant/research support from and has served as a consultant for Merck & Co., Inc., Lexicon Pharmaceuticals, Inc./Novartis Pharmaceuticals Corporation, and MOREHealth. She has also served on the board for Lexicon Pharmaceuticals, Inc. and Ipsen.

**Jordan D. Berlin, MD**, Panel Member, has disclosed that he has received grant/research support from EMD Serono, Inc.; Symphogen Inc.; Incyte Corporation; BeiGene, Ltd.; Roche Laboratories, Inc.; Five Prime Therapeutics, Inc.; and Karyopharm Therapeutics Inc. He has also served on the advisory board for ARMO BioSciences, Inc.; Rafael Pharmaceuticals, Inc.; Five Prime Therapeutics, Inc.; EMD Serono, Inc.; Erytech Pharma; Symphogen Inc.; Celgene Corporation; AbbVie Inc.; AstraZeneca Pharmaceuticals LP; and Gritstone Oncology.

**Daniel Halperin, MD**, Panel Member, has disclosed that he has received consulting fees/honoraria from AbbVie, Inc., Ipsen, Lexion Pharmaceuticals, Inc., and Novartis Pharmaceuticals Corporation; and that he has received grant/research support from Genentech, Inc., Ipsen, Novartis Pharmaceuticals Corporation, and Tarveda Therapeutics.

**Jennifer Chan, MD**, Panel Member, has disclosed that she has received consulting fees/honoraria from Advanced Accelerator Applications USA, Inc., Ipsen, and Novartis Pharmaceuticals Corporation, and that she has equity interest/stock options in Merck & Co., Inc.

**Jennifer L. Burns**, Guidelines Coordinator, NCCN, has disclosed that she has no relevant financial relationships.

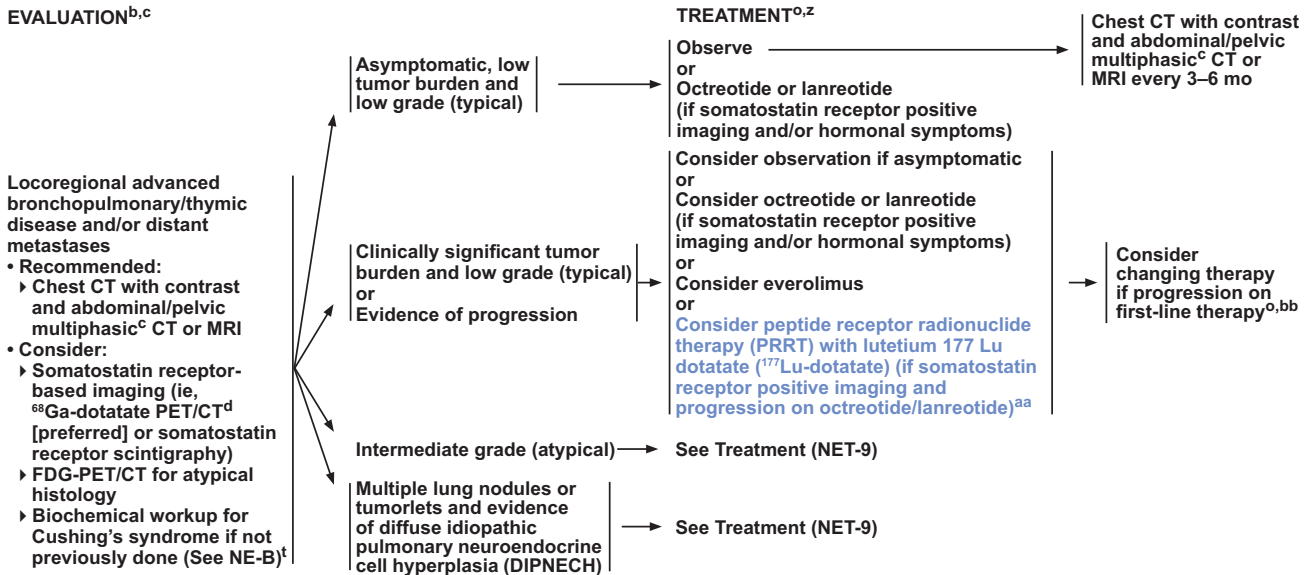
**Ndiya Ogba, PhD**, Oncology Scientist/Medical Writer, NCCN, has disclosed that she has no relevant financial relationships.

**Griselda Zuccarino-Catania, PhD**, Oncology Scientist/Medical Writer, NCCN, has disclosed that her spouse is employed by Janssen Pharmaceuticals, Inc.

This activity is supported by educational grants from AstraZeneca, Celldex Therapeutics, Celgene Corporation, Genentech, Jazz Pharmaceuticals, Inc., Novartis Pharmaceuticals Corporation, and Seattle Genetics, Inc. This activity is supported by independent educational grants from AbbVie, Merck & Co., Inc. and NOVOCURE.

# Neuroendocrine and Adrenal Tumors, Version 2.2018

## MANAGEMENT OF LOCOREGIONAL ADVANCED DISEASE AND/OR DISTANT METASTASES<sup>o,o</sup> BRONCHOPULMONARY OR THYMUS EVALUATION<sup>b,c</sup>



<sup>b</sup>See Principles of Biochemical Testing (NE-B).  
<sup>c</sup>Multiphasic imaging studies are performed with IV contrast.  
<sup>d</sup><sup>68</sup>Ga-dototate PET/CT is more sensitive than somatostatin receptor scintigraphy for determining somatostatin receptor status. PET/CT of skull base to mid-thigh; CT with IV contrast when possible. PET/CT of skull base to mid-thigh; CT with IV contrast when possible. Data are limited on the optimal timing of scans following administration of somatostatin analogs.  
<sup>e</sup>See Surgical Principles for Management of Neuroendocrine Tumors (NE-C).  
<sup>o</sup>See Principles of Systemic Anti-Tumor Therapy (NE-D).  
<sup>t</sup>If Cushing's syndrome suspected, assess for and treat ectopic sources of ACTH production.  
<sup>z</sup>Neuroendocrine tumors are highly heterogeneous and all elements need to be considered (eg, burden of disease, symptoms, histopathology, rate of growth) when determining the best course of treatment.  
<sup>aa</sup>See Principles of Peptide Receptor Radionuclide Therapy (PRRT) with lutetium 177 Lu-dototate (<sup>177</sup>Lu-Dototate) (NE-E).  
<sup>bb</sup>If disease progression, treatment with octreotide or lanreotide should be continued in patients with functional tumors and may be used in combination with any of the subsequent options. For details on the administration of octreotide or lanreotide with <sup>177</sup>Lu-dototate, see NE-E.

Version 2.2018 © National Comprehensive Cancer Network, Inc. 2018. All rights reserved. The NCCN Guidelines<sup>®</sup> and this illustration may not be reproduced in any form without the express written permission of NCCN<sup>®</sup>.

NET-8

### NCCN Categories of Evidence and Consensus

**Category 1:** Based upon high-level evidence, there is uniform NCCN consensus that the intervention is appropriate.

**Category 2A:** Based upon lower-level evidence, there is uniform NCCN consensus that the intervention is appropriate.

**Category 2B:** Based upon lower-level evidence, there is NCCN consensus that the intervention is appropriate.

**Category 3:** Based upon any level of evidence, there is major NCCN disagreement that the intervention is appropriate.

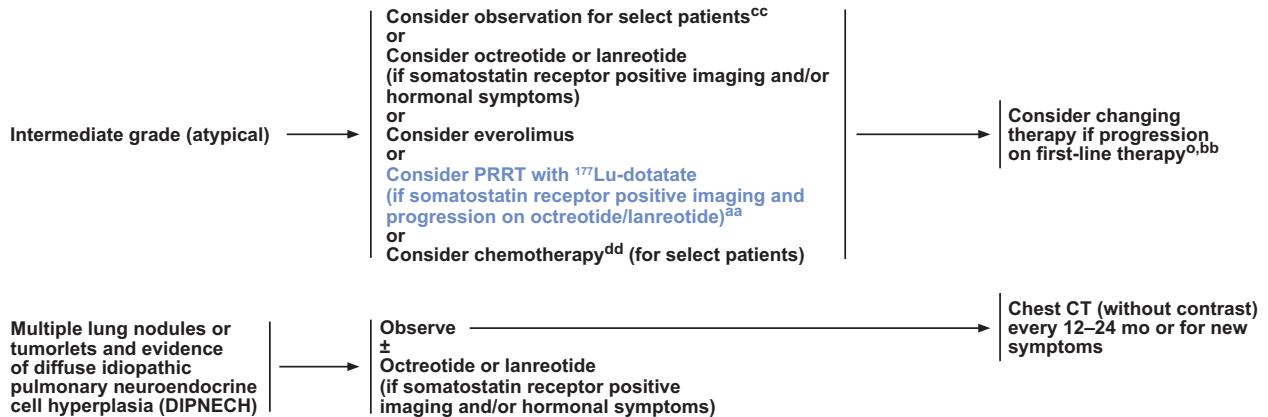
All recommendations are category 2A unless otherwise noted.

Clinical trials: NCCN believes that the best management for any patient with cancer is in a clinical trial. Participation in clinical trials is especially encouraged.

### Overview

Neuroendocrine tumors (NETs) are thought to arise from cells throughout the diffuse endocrine system. NETs comprise a broad family of tumors, the most common of which are in the gastrointestinal tract, lung, thymus, and pancreas. Sites of origin within the gastrointestinal tract include the stomach, small intestine, appendix, and rectum.<sup>1,2</sup> Patients with gastrointestinal NETs may have symptoms attributable to hormonal hypersecretion, which include intermittent flushing and diarrhea.<sup>3</sup> An analysis of the SEER database estimated that the incidence of NETs in the United States was 6.98 cases per 100,000 people in 2012.<sup>1</sup> This analysis suggests that the incidence of NETs is increasing, and that the prevalence of individuals with NETs in the United States may exceed 170,000.<sup>1</sup> Other independent analyses of the SEER database also found that the incidence of gastrointestinal NETs increased from 1975 to 2008.<sup>4,5</sup> The reasons for this increase are unclear, although it is

## Neuroendocrine and Adrenal Tumors, Version 2.2018

MANAGEMENT OF LOCOREGIONAL ADVANCED DISEASE AND/OR DISTANT METASTASES<sup>o,o</sup>  
BRONCHOPULMONARY OR THYMUSTREATMENT<sup>o,z</sup>

<sup>o</sup>See Principles of Systemic Anti-Tumor Therapy (NE-D).

<sup>z</sup>Neuroendocrine tumors are highly heterogeneous and all elements need to be considered (eg, burden of disease, symptoms, histopathology, rate of growth) when determining the best course of treatment.

<sup>aa</sup>See Principles of PRRT with <sup>177</sup>Lu-Dotatate (NE-E).

<sup>bb</sup>If disease progression, treatment with octreotide or lanreotide should be continued in patients with functional tumors and may be used in combination with any of the subsequent options. For details on the administration of octreotide or lanreotide with <sup>177</sup>Lu-dotatate, see NE-E.

<sup>cc</sup>Observation can be considered for tumors on the lower end of the spectrum.

<sup>dd</sup>For primary therapy, cisplatin/etoposide, carboplatin/etoposide, or temozolomide can be considered for intermediate-grade/atypical tumors with Ki-67 proliferative index and mitotic index in the higher end of the defined spectrum.

Version 2.2018 © National Comprehensive Cancer Network, Inc. 2018. All rights reserved. The NCCN Guidelines® and this illustration may not be reproduced in any form without the express written permission of NCCN®.

NET-9

likely that improved diagnosis and classification are contributing factors.<sup>6</sup>

Histopathologic assessment is important in determining prognosis and individualizing therapy.<sup>7</sup> According to the WHO classification of NETs, low-grade (G1) tumors are usually slow growing; intermediate-grade (G2) tumors are more heterogeneous, well-differentiated, and more aggressive (relative to G1); and high-grade (G3) tumors are poorly differentiated, aggressive, and characterized by poor outcomes.<sup>8,9</sup> In terms of median survival, prognosis for patients with well-differentiated and low- or intermediate-grade tumors is better compared with those with high-grade NETs; however, regardless of tumor grade, patients with distant metastasis experience poorer outcomes.<sup>1</sup> Therapeutic options for locoregional advanced disease and distant metastasis include somatostatin analogs (SSAs) to regulate hormone secretion and tumor growth,<sup>10–12</sup> hepatic-directed therapies for liver-predominant disease,<sup>13–16</sup> molecularly targeted agents such as everolimus<sup>17–19</sup>

for antitumor effects, and cytotoxic chemotherapy. However, additional therapeutic options are needed to manage distant metastatic NETs.<sup>20</sup>

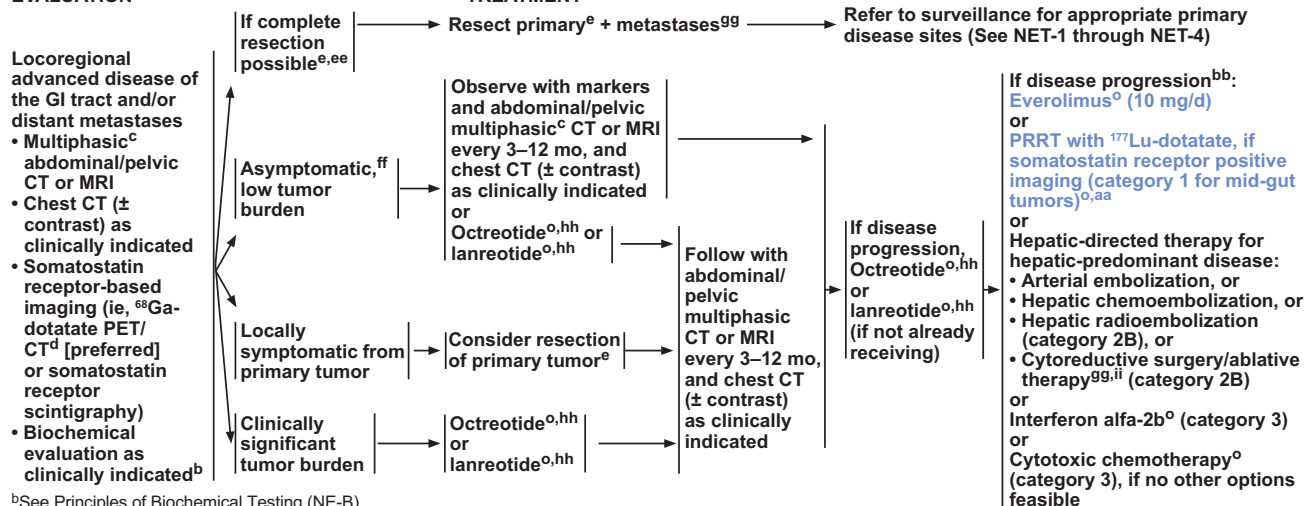
The NCCN Clinical Practice Guidelines in Oncology (NCCN Guidelines) for Neuroendocrine and Adrenal Tumors discuss the diagnosis and management of both sporadic and hereditary NETs based on current evidence. The panel updates the guidelines annually, with additional interim updates as required. These NCCN Guidelines Insights discuss updates to the 2018 version of the NCCN Guidelines, and summarize the management options for locoregional advanced and/or metastatic NETs of the gastrointestinal tract, bronchopulmonary region, and thymus.

## Summary of 2018 Updates and Management Options

### Somatostatin Analogs

Most NETs overexpress high-affinity receptors for somatostatin, a peptide hormone generated by the

## Neuroendocrine and Adrenal Tumors, Version 2.2018

MANAGEMENT OF LOCOREGIONAL ADVANCED DISEASE AND/OR DISTANT METASTASES<sup>c</sup>  
GASTROINTESTINAL TRACTEVALUATION<sup>b,c</sup>

<sup>b</sup>See Principles of Biochemical Testing (NE-B).

<sup>c</sup>Multiphasic imaging studies are performed with IV contrast.

<sup>d</sup><sup>68</sup>Ga-dotatate PET/CT is more sensitive than somatostatin receptor scintigraphy for determining somatostatin receptor status. PET/CT of skull base to mid-thigh; CT with IV contrast when possible. Data are limited on the optimal timing of scans following administration of somatostatin analogs.

<sup>e</sup>See Surgical Principles for Management of Neuroendocrine Tumors (NE-C).

<sup>ff</sup>See Principles of Systemic Anti-Tumor Therapy (NE-D).

<sup>aa</sup>See Principles of PRRT with <sup>177</sup>Lu-Dotatate (NE-E).

<sup>bb</sup>If disease progression, treatment with octreotide or lanreotide should be continued in patients with functional tumors and may be used in combination with any of the subsequent options. For details on the administration of octreotide or lanreotide with <sup>177</sup>Lu-dotatate, see NE-E.

<sup>ee</sup>Noncurative debulking surgery might be considered in select cases.

<sup>ff</sup>Resection of a small asymptomatic (relatively stable) primary in the presence of unresectable metastatic disease is not indicated. However, taking a careful history is recommended as surgery may be an option for asymptomatic patients with previous, intermittent obstructions.

<sup>gg</sup>Includes ablative techniques such as radiofrequency, microwave, and cryotherapy. There are no randomized clinical trials and prospective data for these interventions are limited. However, data on the use of these interventions are emerging.

<sup>hh</sup>Treatment with octreotide or lanreotide will likely only benefit those patients who are somatostatin receptor positive.

<sup>ii</sup>Only if near complete resection can be achieved.

Version 2.2018 © National Comprehensive Cancer Network, Inc. 2018. All rights reserved. The NCCN Guidelines<sup>®</sup> and this illustration may not be reproduced in any form without the express written permission of NCCN<sup>®</sup>.

NET-10

hypothalamus that blocks the release of growth hormones.<sup>21</sup> Somatostatin receptors are also expressed in other parts of the body, including the gastrointestinal tract and pancreas, and inhibit cell proliferation.<sup>21,22</sup> Because native somatostatin rapidly degrades, more stable, synthetic SSAs, including octreotide and lanreotide, were developed to harness the therapeutic utility of somatostatins, regulating hormone-related symptoms and tumor growth.<sup>21</sup>

In patients with locoregional advanced and/or metastatic gastrointestinal tract primary NETs with clinically significant tumor burden or progressive disease, initiation of either octreotide long-acting release (LAR) or lanreotide is recommended to potentially control tumor growth (see NET-10, see above). The recommendation to consider octreotide LAR in these patients is based on the results of the PROM-ID study, a phase III trial of 85 patients with locally inoperable or metastatic midgut NETs (Ki-67 proliferative index, up to 2%), which showed median times to tumor progression of 14.3 and 6 months in

the octreotide LAR and placebo groups, respectively ( $P=.000072$ ).<sup>12</sup> After 6 months of treatment, stable disease was observed in 66.7% of patients in the octreotide LAR group and in 37.2% of those in the placebo group. After long-term follow-up, median overall survival (OS) was not significantly different between the arms (84.7 and 83.7 months, respectively; hazard ratio [HR], 0.83; 95% CI, 0.44–1.46;  $P=.51$ ).<sup>23</sup> However, poststudy treatment included octreotide LAR in 38 of 43 patients in the placebo arm, possibly confounding interpretation of long-term survival results.

The recommendation for lanreotide is based on results of the CLARINET study, which randomized 204 patients with locally advanced or metastatic nonfunctioning pancreatic or intestinal NETs (Ki-67 proliferative index, up to 10%) to receive either lanreotide or placebo, and patients were followed for progression-free survival (PFS). Results from this trial showed that treatment with lanreotide for 2 years resulted in an improvement in PFS over placebo



## Neuroendocrine and Adrenal Tumors, Version 2.2018

(PFS, not reached vs 18 months, respectively; HR, 0.47; 95% CI, 0.30–0.73;  $P < .001$ ).<sup>10</sup> Subsequent data from a preplanned interim analysis of the open-label extension of the CLARINET study estimated PFS in patients treated with lanreotide at 32.8 months (95% CI, 30.9–68.0).<sup>24</sup> The difference in the reported median PFS between the PROMID and CLARINET studies is likely explained by a difference in the study populations—most patients enrolled in the CLARINET trial experienced stable disease in the 3 to 6 months before randomization.<sup>10</sup>

Patients with locoregional advanced disease and/or distant metastases of bronchopulmonary or thymic NETs can also be treated with octreotide or lanreotide (see NET-8 and -9, pages 695 and 696). Although rare, some patients may present with multiple lung nodules or tumorlets and widespread peripheral airway neuroendocrine cell hyperplasia. In this case, a diagnosis of diffuse idiopathic pulmonary neuroendocrine cell hyperplasia can be made.<sup>25</sup> This condition is generally indolent; however, if patients present with somatostatin receptor–positive disease and/or hormonal symptoms, treatment with octreotide or lanreotide is recommended. No clear consensus exists on the timing of initiation of octreotide or lanreotide in patients with gastrointestinal tract, bronchopulmonary, or thymic NETs, and either immediate treatment initiation or deferring initiation until evidence of progression is seen may be appropriate in selected patients.

### Advances in Treatment of Carcinoid Syndrome Beyond SSAs

Patients with metastatic NETs and carcinoid syndrome should be treated with octreotide or lanreotide.<sup>26</sup> Standard doses of octreotide LAR are 20 to 30 mg intramuscularly every 4 weeks. Short-acting octreotide (usually 150–250 mcg subcutaneously, 3 times daily) can be added to octreotide LAR or lanreotide for rapid relief of symptoms or for breakthrough symptoms.<sup>11,27,28</sup> If diarrhea is poorly controlled, telotristat should be considered. Telotristat or telotristat ethyl is a novel small molecule tryptophan hydroxylase inhibitor that decreases urinary 5-HIAA levels and the frequency of bowel movements in patients with carcinoid syndrome.<sup>29,30</sup> It was FDA-approved in February 2017, and the recommendation for its use to treat persistent diarrhea

in this context is based on the results of the phase III TELESTAR study.

### Peptide Receptor Radionuclide Therapy

Several studies initially reported that treatment with radiolabeled SSAs was associated with tumor responses in patients with advanced NETs.<sup>31–35</sup> A prospective phase II study of radiolabeled peptide therapy in 90 patients with metastatic NETs refractory to octreotide showed that treatment was associated with improvement in symptoms; radiographic regression, however, was relatively uncommon.<sup>36</sup> Numerous large nonrandomized cohort analyses have also reported encouraging survival rates with this approach.<sup>37–39</sup> A recent phase III study, NETTER-1, randomized 229 patients with advanced midgut NETs to receive treatment with either lutetium 177 (<sup>177</sup>Lu)-DOTATATE or high-dose octreotide.<sup>40</sup> Results showed that treatment with <sup>177</sup>Lu-DOTATATE was associated with a significant improvement in PFS (not reached vs 8.4 months;  $P < .0001$ ).<sup>40</sup> Objective tumor responses were observed in 18% of patients who received <sup>177</sup>Lu-DOTATATE versus 3% in the control group ( $P < .001$ ).<sup>40</sup> A recent study examined the long-term efficacy, survival, and toxicity of <sup>177</sup>Lu-DOTATATE in a group of 610 Dutch patients with metastatic gastroenteropancreatic (GEP) NETs and bronchial NETs.<sup>41</sup> PFS and OS for all patients with NETs were 29 months (95% CI, 26–33) and 63 months (95% CI, 55–72), respectively.<sup>41</sup>

Peptide receptor radionuclide therapy (PRRT) with <sup>177</sup>Lu-DOTATATE was approved by the FDA in January 2018 for the treatment of adult patients with unresectable, low- or intermediate-grade, locally advanced or metastatic GEP NETs. During an interim meeting in 2018, the NCCN panel included PRRT with <sup>177</sup>Lu-DOTATATE as a treatment option for some advanced and/or metastatic gastrointestinal tract, bronchopulmonary, and thymic NETs (category 1 for midgut tumors) (see NET-8, -9, -10, pages 695, 696, and 697, respectively). For details on other NET sites recommended for PRRT with <sup>177</sup>Lu-DOTATATE and principles of administration, please refer to the full version of these NCCN Guidelines (available at NCCN.org).

### Everolimus

For patients with progressive metastatic gastrointestinal tract and bronchopulmonary NETs or intermedi-

## Neuroendocrine and Adrenal Tumors, Version 2.2018

ate-grade (atypical) bronchopulmonary NETs, everolimus is a recommended treatment option. Everolimus is an mTOR inhibitor that was well tolerated and showed evidence of antitumor effects in patients with advanced NETs when given with octreotide LAR in a phase II trial.<sup>42</sup> In the randomized phase III RADIANT-2 trial, 429 patients with advanced NETs and carcinoid syndrome were randomized to receive octreotide LAR with everolimus or placebo.<sup>17</sup> Based on central review, patients receiving octreotide plus everolimus had a median PFS of 16.4 months compared with 11.3 for those receiving octreotide alone ( $P=.026$ ). This difference in the primary end point of PFS did not, however, meet the predefined threshold for statistical significance.

A subsequent phase III trial, RADIANT-4, randomized 302 patients with progressive nonfunctional gastrointestinal tract or lung NETs 2:1 to receive either everolimus or placebo.<sup>18</sup> In contrast to RADIANT-2, patients in RADIANT-4 were not receiving an SSA at the time of study enrollment, and concurrent SSA was not a study requirement. Median PFS was 11.0 months (95% CI, 9.2–13.3) in the everolimus arm and 3.9 (95% CI, 3.6–7.4) in the placebo arm. The HR for progression or death was 0.48 (95% CI, 0.35–0.67;  $P<.001$ ). Drug-related grade 3/4 adverse events included stomatitis (9% vs 0%), infections (7% vs 0%), diarrhea (7% vs 2%), anemia (4% vs 1%), fatigue (3% vs 1%), and hyperglycemia (3% vs 0%). A report highlighted the outcomes of 169 pretreated patients with advanced NETs of the pancreas ( $n=85$ ) or other sites ( $n=84$ ), including jejunum-ileum ( $n=21$ ) and lung tumors ( $n=22$ ), who received everolimus through a compassionate use program.<sup>43</sup> An increased risk of adverse events was noted in patients who had received previous PRRT or chemotherapy. During the 2018 Neuroendocrine and Adrenal Tumors Guidelines Panel meeting, the panel clarified that everolimus is a recommended option for progressive metastatic gastrointestinal tract NETs (everolimus was previously noted as an option to consider; see NET-10, page 697).

### Hepatic-Directed Therapies

For patients with unresectable, hepatic-predominant, progressive gastrointestinal tract NETs, hepatic-directed therapies may be considered, mainly with the palliative goals of extending life and relieving hormonal symptoms.<sup>13–16</sup>

Cytoreductive surgery or ablative therapies such as radiofrequency ablation or cryoablation may be considered if near complete treatment of tumor burden can be achieved (category 2B).<sup>44–48</sup> For unresectable liver metastases, hepatic regional therapy (arterial embolization,<sup>49</sup> chemoembolization,<sup>50–52</sup> or radioembolization [category 2B])<sup>53–55</sup> is recommended. No single modality of embolization therapy has been shown to be superior to another, but there is a difference in both long- and short-term toxicities among the different modalities.

### Resection of Metastatic Disease

In some cases, patients with limited hepatic metastases or other sites of disease can undergo complete resection of the primary tumor and metastases with curative intent. One study of 172 patients who underwent hepatic resection of metastatic NETs showed that long-term survival can be achieved in selected cases: the reported 10-year OS rate was 50.4%.<sup>56</sup> A systematic review reported 5-year OS rates ranging from 41% to 100% in patients undergoing hepatic resection.<sup>57</sup> A recent study of 800 patients with advanced pancreatic and gastrointestinal tract NETs who underwent cytoreductive surgery showed a median OS of 161 months in those with gastrointestinal tract NETs<sup>58</sup>; the 5-, 10-, and 20-year OS rates were 84%, 67%, and 31%, respectively.<sup>58</sup> Most patients with resected metastatic disease, however, will eventually experience recurrence.<sup>59,60</sup> Noncurative debulking surgery can also be considered in select cases, especially if the patient is symptomatic from either tumor bulk or hormone production.

Resection of the primary site in the setting of unresectable metastases is generally not indicated if the primary site remains asymptomatic and is relatively stable.<sup>57</sup> A recent retrospective study did not find a survival improvement associated with resecting asymptomatic primary small bowel tumors.<sup>61</sup> However, it is not uncommon for patients with small bowel primary tumors to experience symptoms of intermittent abdominal pain from episodic bowel obstruction or bowel ischemia related to the primary tumor and surrounding fibrosis. Palliative small bowel resection is recommended in these patients. If resection is performed and future treatment with octreotide or lanreotide is anticipated, a prophylactic cholecystectomy can be considered given the association between

## Neuroendocrine and Adrenal Tumors, Version 2.2018

long-term treatment with SSAs and the development of biliary symptoms and gallstones.<sup>26</sup>

### Interferon-alfa

In several large nonrandomized series, interferon-alfa has been shown to be associated with an anti-tumor effect in patients with advanced gastrointestinal tract NETs.<sup>28,62–64</sup> In a recent large randomized study led by SWOG, treatment with interferon alfa-2b was compared with bevacizumab in 427 patients with progressive NETs.<sup>65</sup> Octreotide was included in both arms of this study. No significant difference in PFS was observed; however, the long PFS durations in both arms of the study (15.4 and 16.6 months for interferon-alfa and bevacizumab, respectively) suggest that both drugs may be active in this setting.<sup>65</sup> Because of its potential side effects, interferon-alfa is usually not initiated until failure of SSA treatment.<sup>66</sup>

### Cytotoxic Chemotherapy

The benefits associated with cytotoxic chemotherapy in patients with advanced gastrointestinal tract NETs appear to be modest at best. Tumor response rates are generally low, and no PFS benefit has been clearly demonstrated.<sup>66</sup> Carboplatin/etoposide, cisplatin/etoposide, or temozolomide may be considered for bronchopulmonary NETs on the higher end of the atypical category with respect to Ki-67, mitotic index, and grade, especially tumors that are poorly differentiated histologically.<sup>67</sup> The following cytotoxic chemotherapy agents may be considered as category 3 recommendations in patients with progressive gastrointestinal tract NETs if no other treatment options exist: 5-fluorouracil (5-FU), capecitabine, dacarbazine, oxaliplatin, streptozocin, and temozolomide.

Capecitabine was tested in patients with metastatic nonpancreatic NETs in a phase II trial; no objective responses were reported, although 13 of 19 patients were reported to have experienced stable disease.<sup>68</sup> The combination of capecitabine and oxaliplatin was assessed in a phase II study, with response rates of 23% in patients with poorly differentiated NETs and 30% in those with well-differentiated disease.<sup>69</sup> 5-FU was assessed in the phase

III E1281 trial in combination with streptozocin or doxorubicin<sup>70</sup>; response rates in both arms were approximately 16%. Dacarbazine was given following progression, with a response rate of 8%. A phase II trial assessing the clinical activity of bevacizumab plus capecitabine in 49 patients with advanced and/or metastatic gastrointestinal NETs<sup>71</sup> reported a median PFS of 23.4 months, with 18% of patients achieving a partial response and 70% achieving stable disease. Similar results were seen in 2 small trials of FOLFOX (fluorouracil/leucovorin/oxaliplatin) and CAPOX (capecitabine/oxaliplatin) combined with bevacizumab, with reported PFS of 19.3 and 16.7 months, respectively.<sup>72</sup> However, these findings have not been confirmed in phase III studies.

Temozolomide is an option for advanced bronchopulmonary and thymic NETs.<sup>73,74</sup> In a retrospective study of 31 patients with progressive metastatic bronchial NETs, temozolomide monotherapy was associated with partial responses in 14%.<sup>73</sup> During the 2018 meeting, the guidelines panel included temozolomide as an option for select patients with locoregional unresectable or metastatic bronchopulmonary or thymic NETs, and clarified the context for chemotherapy use in this setting (see NET-9, page 696).

## Conclusions

During the NCCN Guidelines Panel meetings for 2018, panel members discussed important updates to the NCCN Guidelines for Neuroendocrine and Adrenal Tumors, including considerations for the management of locoregional advanced disease and/or distant metastasis from NETs of the gastrointestinal tract, bronchopulmonary, or thymic regions. Patients with advanced NETs and progressive disease face worse survival outcomes; therefore, a need for additional therapeutic options exists. The development of novel treatment options intensifies the need to standardize optimal selection, timing, and sequencing of treatment.<sup>75</sup> Future clinical studies have the potential to uncover novel options and improve treatment recommendations.

## References

1. Dasari A, Shen C, Halperin D, et al. Trends in the incidence, prevalence, and survival outcomes in patients with neuroendocrine tumors in the United States. *JAMA Oncol* 2017;3:1335–1342.
2. Yao JC, Hassan M, Phan A, et al. One hundred years after “carcinoid”: epidemiology of and prognostic factors for neuroendocrine tumors in 35,825 cases in the United States. *J Clin Oncol* 2008;26:3063–3072.
3. Jenson RT, Norton JA. Carcinoid tumors and carcinoid syndrome. In: DeVita VT, Hellman S, Rosenberg SA, eds. *Cancer: Principles and Practice*



## Neuroendocrine and Adrenal Tumors, Version 2.2018

- of Oncology, Vol 2, 6th edition. Philadelphia, PA: Lippincott Williams and Wilkins; 2001:1813–1826.
4. Fraenkel M, Kim M, Faggiano A, et al. Incidence of gastroenteropancreatic neuroendocrine tumours: a systematic review of the literature. *Endocr Relat Cancer* 2014;21:R153–163.
  5. Tsikitis VL, Wertheim BC, Guerrero MA. Trends of incidence and survival of gastrointestinal neuroendocrine tumors in the United States: a SEER analysis. *J Cancer* 2012;3:292–302.
  6. Hallet J, Law CH, Cukier M, et al. Exploring the rising incidence of neuroendocrine tumors: a population-based analysis of epidemiology, metastatic presentation, and outcomes. *Cancer* 2015;121:589–597.
  7. Lee MS, O'Neil BH. Summary of emerging personalized medicine in neuroendocrine tumors: are we on track? *J Gastrointest Oncol* 2016;7:804–818.
  8. Deroose CM, Hindie E, Kebebew E, et al. Molecular imaging of gastroenteropancreatic neuroendocrine tumors: current status and future directions. *J Nucl Med* 2016;57:1949–1956.
  9. Rindi G, Petrone G, Inzani F. The 2010 WHO classification of digestive neuroendocrine neoplasms: a critical appraisal four years after its introduction. *Endocr Pathol* 2014;25:186–192.
  10. Caplin ME, Pavel M, Cwikla JB, et al. Lanreotide in metastatic enteropancreatic neuroendocrine tumors. *N Engl J Med* 2014;371:224–233.
  11. Kvols LK, Moertel CG, O'Connell MJ, et al. Treatment of the malignant carcinoid syndrome. Evaluation of a long-acting somatostatin analogue. *N Engl J Med* 1986;315:663–666.
  12. Rinke A, Muller HH, Schade-Brittinger C, et al. Placebo-controlled, double-blind, prospective, randomized study on the effect of octreotide LAR in the control of tumor growth in patients with metastatic neuroendocrine midgut tumors: a report from the PROMID Study Group. *J Clin Oncol* 2009;27:4656–4663.
  13. Johnston FM, Mavros MN, Herman JM, Pawlik TM. Local therapies for hepatic metastases. *J Natl Compr Canc Netw* 2013;11:153–160.
  14. Jones NB, Shah MH, Bloomston M. Liver-directed therapies in patients with advanced neuroendocrine tumors. *J Natl Compr Canc Netw* 2012;10:765–774.
  15. Kennedy A, Bester L, Salem R, et al. Role of hepatic intra-arterial therapies in metastatic neuroendocrine tumours (NET): guidelines from the NET-Liver-Metastases Consensus Conference. *HPB (Oxford)* 2015;17:29–37.
  16. Lewis MA, Hubbard J. Multimodal liver-directed management of neuroendocrine hepatic metastases. *Int J Hepatol* 2011;2011:452343.
  17. Pavel ME, Hainsworth JD, Baudin E, et al. Everolimus plus octreotide long-acting repeatable for the treatment of advanced neuroendocrine tumours associated with carcinoid syndrome (RADIANT-2): a randomised, placebo-controlled, phase 3 study. *Lancet* 2011;378:2005–2012.
  18. Yao JC, Fazio N, Singh S, et al. Everolimus for the treatment of advanced, non-functional neuroendocrine tumours of the lung or gastrointestinal tract (RADIANT-4): a randomised, placebo-controlled, phase 3 study. *Lancet* 2016;387:968–977.
  19. Yao JC, Lombard-Bohas C, Baudin E, et al. Daily oral everolimus activity in patients with metastatic pancreatic neuroendocrine tumors after failure of cytotoxic chemotherapy: a phase II trial. *J Clin Oncol* 2010;28:69–76.
  20. Kulke MH, Siu LL, Tepper JE, et al. Future directions in the treatment of neuroendocrine tumors: consensus report of the National Cancer Institute Neuroendocrine Tumor clinical trials planning meeting. *J Clin Oncol* 2011;29:934–943.
  21. Oberg KE, Reubi JC, Kwekkeboom DJ, Krenning EP. Role of somatostatins in gastroenteropancreatic neuroendocrine tumor development and therapy. *Gastroenterology* 2010;139:742–753, 753.e1.
  22. Pyronnet S, Bousquet C, Najib S, et al. Antitumor effects of somatostatin. *Mol Cell Endocrinol* 2008;286:230–237.
  23. Rinke A, Wittenberg M, Schade-Brittinger C, et al. Placebo-Controlled, double-blind, prospective, randomized study on the effect of octreotide LAR in the control of tumor growth in patients with metastatic neuroendocrine midgut tumors (PROMID): results of long-term survival. *Neuroendocrinology* 2017;104:26–32.
  24. Caplin ME, Pavel M, Cwikla JB, et al. Anti-tumour effects of lanreotide for pancreatic and intestinal neuroendocrine tumours: the CLARINET open-label extension study. *Endocr Relat Cancer* 2016;23:191–199.
  25. Travis WD. Advances in neuroendocrine lung tumors. *Ann Oncol* 2010;21(Suppl 7):vii65–71.
  26. Oberg K, Kvols L, Caplin M, et al. Consensus report on the use of somatostatin analogs for the management of neuroendocrine tumors of the gastroenteropancreatic system. *Ann Oncol* 2004;15:966–973.
  27. Brentjens R, Saltz L. Islet cell tumors of the pancreas: the medical oncologist's perspective. *Surg Clin North Am* 2001;81:527–542.
  28. Janson ET, Oberg K. Long-term management of the carcinoid syndrome. Treatment with octreotide alone and in combination with alpha-interferon. *Acta Oncol* 1993;32:225–229.
  29. Kulke MH, O'Dorisio T, Phan A, et al. Telotristat etiprate, a novel serotonin synthesis inhibitor, in patients with carcinoid syndrome and diarrhea not adequately controlled by octreotide. *Endocr Relat Cancer* 2014;21:705–714.
  30. Pavel M, Horsch D, Caplin M, et al. Telotristat etiprate for carcinoid syndrome: a single-arm, multicenter trial. *J Clin Endocrinol Metab* 2015;100:1511–1519.
  31. Imhof A, Brunner P, Marincek N, et al. Response, survival, and long-term toxicity after therapy with the radiolabeled somatostatin analogue [90Y-DOTA]-TOC in metastasized neuroendocrine cancers. *J Clin Oncol* 2011;29:2416–2423.
  32. Krenning EP, Teunissen JJ, Valkema R, et al. Molecular radiotherapy with somatostatin analogs for (neuro-)endocrine tumors. *J Endocrinol Invest* 2005;28:146–150.
  33. Kwekkeboom DJ, Bakker WH, Kam BL, et al. Treatment of patients with gastro-entero-pancreatic (GEP) tumours with the novel radiolabelled somatostatin analogue [177Lu-DOTA(0),Tyr3]octreotate. *Eur J Nucl Med Mol Imaging* 2003;30:417–422.
  34. Kwekkeboom DJ, Teunissen JJ, Bakker WH, et al. Radiolabeled somatostatin analog [177Lu-DOTA0,Tyr3]octreotate in patients with endocrine gastroenteropancreatic tumors. *J Clin Oncol* 2005;23:2754–2762.
  35. Kwekkeboom DJ, Teunissen JJM, Kam BL, et al. Treatment of patients who have endocrine gastroenteropancreatic tumors with radiolabeled somatostatin analogues. *Hematol Oncol Clin North Am* 2007;21:561–573.
  36. Bushnell DL Jr, O'Dorisio TM, O'Dorisio MS, et al. 90Y-edotreotide for metastatic carcinoid refractory to octreotide. *J Clin Oncol* 2010;28:1652–1659.
  37. Kong G, Thompson M, Collins M, et al. Assessment of predictors of response and long-term survival of patients with neuroendocrine tumour treated with peptide receptor chemoradionuclide therapy (PRCRT). *Eur J Nucl Med Mol Imaging* 2014;41:1831–1844.
  38. Villard L, Romer A, Marincek N, et al. Cohort study of somatostatin-based radiolabeled peptide therapy with [(90)Y-DOTA]-TOC versus [(90)Y-DOTA]-TOC plus [(177)Lu-DOTA]-TOC in neuroendocrine cancers. *J Clin Oncol* 2012;30:1100–1106.
  39. Horsch D, Eziddin S, Haug A, et al. Peptide receptor radionuclide therapy for neuroendocrine tumors in Germany: first results of a multi-institutional cancer registry. *Recent Results Cancer Res* 2013;194:457–465.
  40. Strosberg J, El-Haddad G, Wolin E, et al. Phase 3 trial of (177)Lu-Dotatate for midgut neuroendocrine tumors. *N Engl J Med* 2017;376:125–135.
  41. Brabander T, van der Zwan WA, Teunissen JJ, et al. long-term efficacy, survival, and safety of [(177)Lu-DOTA(0),Tyr(3)]octreotate in patients with gastroenteropancreatic and bronchial neuroendocrine tumors. *Clin Cancer Res* 2017;23:4617–4624.
  42. Yao JC, Phan AT, Chang DZ, et al. Efficacy of RAD001 (everolimus) and octreotide LAR in advanced low- to intermediate-grade neuroendocrine tumors: results of a phase II study. *J Clin Oncol* 2008;26:4311–4318.
  43. Panzuto F, Rinzivillo M, Fazio N, et al. Real-world study of everolimus in advanced progressive neuroendocrine tumors. *Oncologist* 2014;19:966–974.
  44. Du S, Ni J, Weng L, et al. Aggressive locoregional treatment improves the outcome of liver metastases from grade 3 gastroenteropancreatic neuroendocrine tumors. *Medicine (Baltimore)* 2015;94:e1429.
  45. Liu DM, Kennedy A, Turner D, et al. Minimally invasive techniques in management of hepatic neuroendocrine metastatic disease. *Am J Clin Oncol* 2009;32:200–215.
  46. Mohan H, Nicholson P, Winter DC, et al. Radiofrequency ablation for neuroendocrine liver metastases: a systematic review. *J Vasc Interv Radiol* 2015;26:935–942 e931.
  47. Siperstein AE, Rogers SJ, Hansen PD, Gitomirsky A. Laparoscopic thermal ablation of hepatic neuroendocrine tumor metastases. *Surgery* 1997;122:1147–1154.
  48. Taner T, Atwell TD, Zhang L, et al. Adjunctive radiofrequency ablation of metastatic neuroendocrine cancer to the liver complements surgical resection. *HPB (Oxford)* 2013;15:190–195.
  49. Strosberg JR, Weber JM, Choi J, et al. A phase II clinical trial of sunitinib following hepatic transarterial embolization for metastatic neuroendocrine tumors. *Ann Oncol* 2012;23:2335–2341.
  50. Gates J, Hartnell GG, Stuart KE, Clouse ME. Chemoembolization of hepatic neoplasms: safety, complications, and when to worry. *Radiographics* 1999;19:399–414.

## Neuroendocrine and Adrenal Tumors, Version 2.2018

51. Hur S, Chung JW, Kim HC, et al. Survival outcomes and prognostic factors of transcatheter arterial chemoembolization for hepatic neuroendocrine metastases. *J Vasc Interv Radiol* 2013;24:947–956; quiz 957.
52. Ruzniwski P, Malka D. Hepatic arterial chemoembolization in the management of advanced digestive endocrine tumors. *Digestion* 2000;62(Suppl 1):79–83.
53. Devic Z, Rosenberg J, Braat AJ, et al. The efficacy of hepatic 90Y resin radioembolization for metastatic neuroendocrine tumors: a meta-analysis. *J Nucl Med* 2014;55:1404–1410.
54. Kalinowski M, Dressler M, Konig A, et al. Selective internal radiotherapy with yttrium-90 microspheres for hepatic metastatic neuroendocrine tumors: a prospective single center study. *Digestion* 2009;79:137–142.
55. Memon K, Lewandowski RJ, Mulcahy MF, et al. Radioembolization for neuroendocrine liver metastases: safety, imaging, and long-term outcomes. *Int J Radiat Oncol Biol Phys* 2012;83:887–894.
56. Glazer ES, Tseng JF, Al-Refaei W, et al. Long-term survival after surgical management of neuroendocrine hepatic metastases. *HPB (Oxford)* 2011;12:427–433.
57. Lesurtel M, Nagorney DM, Mazzaferro V, et al. When should a liver resection be performed in patients with liver metastases from neuroendocrine tumours? A systematic review with practice recommendations. *HPB (Oxford)* 2015;17:17–22.
58. Woltering EA, Voros BA, Beyer DT, et al. Aggressive surgical approach to the management of neuroendocrine tumors: a report of 1,000 surgical cytoreductions by a single institution. *J Am Coll Surg* 2017;224:434–447.
59. Mayo SC, de Jong MC, Pulitano C, et al. Surgical management of hepatic neuroendocrine tumor metastasis: results from an international multi-institutional analysis. *Ann Surg Oncol* 2010;17:3129–3136.
60. Saxena A, Chua TC, Perera M, et al. Surgical resection of hepatic metastases from neuroendocrine neoplasms: a systematic review. *Surg Oncol* 2012;21:e131–141.
61. Daskalakis K, Karakatsanis A, Hessman O, et al. Association of a prophylactic surgical approach to stage IV small intestinal neuroendocrine tumors with survival. *JAMA Oncol* 2018;4:183–189.
62. Faiss S, Pape UF, Bohmig M, et al. Prospective, randomized, multicenter trial on the antiproliferative effect of lanreotide, interferon alfa, and their combination for therapy of metastatic neuroendocrine gastroenteropancreatic tumors—the International Lanreotide and Interferon Alfa Study Group. *J Clin Oncol* 2003;21:2689–2696.
63. Fazio N, de Braud F, Delle Fave G, Oberg K. Interferon-alpha and somatostatin analog in patients with gastroenteropancreatic neuroendocrine carcinoma: single agent or combination? *Ann Oncol* 2007;18:13–19.
64. Kolby L, Persson G, Franzen S, Ahren B. Randomized clinical trial of the effect of interferon alpha on survival in patients with disseminated midgut carcinoid tumours. *Br J Surg* 2003;90:687–693.
65. Yao JC, Guthrie KA, Moran C, et al. Phase III prospective randomized comparison trial of depot octreotide plus interferon alfa-2b versus depot octreotide plus bevacizumab in patients with advanced carcinoid tumors: SWOG S0518. *J Clin Oncol* 2017;35:1695–1703.
66. Paulson AS, Bergsland EK. Systemic therapy for advanced carcinoid tumors: where do we go from here? *J Natl Compr Canc Netw* 2012;10:785–793.
67. Chong CR, Wirth LJ, Nishino M, et al. Chemotherapy for locally advanced and metastatic pulmonary carcinoid tumors. *Lung Cancer* 2014;86:241–246.
68. Medley L, Morel AN, Farrugia D, et al. Phase II study of single agent capecitabine in the treatment of metastatic non-pancreatic neuroendocrine tumours. *Br J Cancer* 2011;104:1067–1070.
69. Bajetta E, Catena L, Procopio G, et al. Are capecitabine and oxaliplatin (XELOX) suitable treatments for progressing low-grade and high-grade neuroendocrine tumours? *Cancer Chemother Pharmacol* 2007;59:637–642.
70. Sun W, Lipsitz S, Catalano P, et al. Phase II/III study of doxorubicin with fluorouracil compared with streptozocin with fluorouracil or dacarbazine in the treatment of advanced carcinoid tumors: Eastern Cooperative Oncology Group study E1281. *J Clin Oncol* 2005;23:4897–4904.
71. Mitty E, Walter T, Baudin E, et al. Bevacizumab plus capecitabine in patients with progressive advanced well-differentiated neuroendocrine tumors of the gastro-intestinal (GI-NETs) tract (BETTER trial)—a phase II non-randomised trial. *Eur J Cancer* 2014;50:3107–3115.
72. Kunz PL, Balise RR, Fehrenbacher L, et al. Oxaliplatin-fluoropyrimidine chemotherapy plus bevacizumab in advanced neuroendocrine tumors: an analysis of 2 phase II trials. *Pancreas* 2016;45:1394–1400.
73. Crona J, Fanola I, Lindholm DP, et al. Effect of temozolomide in patients with metastatic bronchial carcinoids. *Neuroendocrinology* 2013;98:151–155.
74. Ekeblad S, Sundin A, Janson ET, et al. Temozolomide as monotherapy is effective in treatment of advanced malignant neuroendocrine tumors. *Clin Cancer Res* 2007;13:2986–2991.
75. Cives M, Strosberg J. Treatment strategies for metastatic neuroendocrine tumors of the gastrointestinal tract. *Curr Treat Options Oncol* 2017;18:14.

### Instructions for Completion

To participate in this journal CE activity: 1) review the learning objectives and author disclosures; 2) study the education content; 3) take the posttest with a 66% minimum passing score and complete the evaluation at <http://education.nccn.org/node/83111>; and 4) view/print certificate. After reading the article, you should be able to answer the following multiple-

choice questions. Credit cannot be obtained for tests completed on paper. You must be a registered user on NCCN.org. If you are not registered on NCCN.org, click on “New Member? Sign up here” link on the left hand side of the Web site to register. Only one answer is correct for each question. Once you successfully answer all posttest questions you will be able to view and/or print your certificate. Software requirements: Internet

### Posttest Questions

1. A 40-year-old man is diagnosed with metastatic bronchopulmonary NET and the pathology report determines the tumors are intermediate grade. Which of the following treatment options may be considered?
  - a. Everolimus
  - b. Interferon alfa-2b plus lanreotide
  - c. Observation
  - d. Etoposide and platinum-based chemotherapy
  - e. a, c, or d
2. Which of the following systemic therapy is not recom-

mended for control of low- or intermediate-grade metastatic NET of GI tract primary?

- a. Everolimus
- b. Octreotide
- c. Lanreotide
- d. PRRT (such as 177Lu-Dotatate)
- e. Etoposide and cisplatin



3. True or False: Telotristat ethyl in combination with octreotide or lanreotide may be considered as a treatment option for poorly controlled diarrhea from carcinoid syndrome.