

# Evolving Roles of Histologic Evaluation and Molecular/Genomic Profiling in the Management of Endometrial Cancer

Rajmohan Murali, MBBS, MD<sup>a</sup>; Deborah F. Delair, MD<sup>a</sup>; Sarah M. Bean, MD<sup>b</sup>; Nadeem R. Abu-Rustum, MD<sup>c,d</sup>; and Robert A. Soslow, MD<sup>a</sup>

## Abstract

Endometrial cancers are the most common gynecologic malignancies. The staging of endometrial cancer has evolved from a clinical-based system to a comprehensive surgical-pathologic approach that allows for better risk stratification and treatment planning. Over the past few years, use of NCCN's sentinel lymph node (SLN) mapping algorithm for the surgical staging of endometrial cancer has gained significant acceptance and is now commonly applied in many practices. However, pathologic evaluation of prognostic factors is beset by challenges, including the reproducibility of histologic classification and FIGO's grading, as well as the questionable clinical significance of low-volume tumor in SLNs. With the revelation of major genomic classes of endometrial cancer comes the potential for improved, reproducible, and prognostically relevant classification schemes, which integrate traditional pathologic parameters with genomic findings, to aid in treatment decisions. Pathologic identification of new variants of endometrial cancer, such as undifferentiated carcinoma, continues to advance the phenotypic spectrum of these tumors, spurring genomic and functional studies to further characterize their mechanistic underpinnings and potentially reveal new avenues for treatment. In the era of precision medicine, pathologic assessment of biomarkers (eg, mismatch repair proteins) and recognition of phenotypes that are amenable to specific targeted therapies (such as *POLE*-mutated tumors) have become integral to the management of women with endometrial carcinoma.

*J Natl Compr Canc Netw* 2018;16(2):201–209  
doi: 10.6004/jnccn.2017.7066

Endometrial cancers constitute more than half of all gynecologic cancer diagnoses in the United States.<sup>1</sup> Pathologic evaluation is an important element of disease management. As management approaches continue to evolve in response to reported data from clinicopathologic and molecular genetic studies, pathology will continue to play a central role in diagnosis, prognostic assessment, and treatment planning.

## Evolution of Surgical-Pathologic Staging

Most patients with endometrial cancer present with abnormal bleeding and undergo initial evaluation with

pelvic ultrasonography and endometrial biopsy/curettage. Histopathologic evaluation of the biopsy/curettage specimen is performed to confirm the diagnosis.<sup>2,3</sup> Early staging schemes were essentially based on clinical findings, but since 1988, a more accurate surgical-pathologic staging approach has been used (Table 1).<sup>4</sup>

## Comprehensive Surgical Staging

Preoperatively, staging is performed to estimate recurrence risk, and is based on the imaging evaluation of myometrial invasion, cervical involvement, and lymph node metastasis. MRI and transvaginal ultrasonography are effective modalities for assessing myometrial and cervical invasion, but imaging is poor at detecting lymph

From the <sup>a</sup>Department of Pathology, Memorial Sloan Kettering Cancer Center, New York, New York; <sup>b</sup>Department of Pathology, Duke University School of Medicine, Durham, North Carolina; <sup>c</sup>Gynecology Service, Department of Surgery, Memorial Sloan Kettering Cancer Center, New York, New York; and <sup>d</sup>Department of Obstetrics and Gynecology, Weill Cornell Medical College, New York, New York.

Submitted October 3, 2017; accepted for publication November 29, 2017.

The authors have disclosed that they have no financial interests,

arrangements, affiliations, or commercial interests with the manufacturers of any products discussed in this article or their competitors.

This work was funded in part through the NIH/NCI Cancer Center Support Grant P30 CA008748.

Correspondence: Nadeem R. Abu-Rustum, MD, Gynecology Service, Department of Surgery, Memorial Sloan Kettering Cancer Center, 1275 York Avenue, New York, NY 10065. E-mail: abu-rusn@mskcc.org

Murali et al

**Table 1. Evolution of FIGO Endometrial Cancer Staging Classification**

	FIGO Staging, 1961–1971	FIGO Staging, 1988	FIGO Staging, 2009
Basis	Clinical	Surgical-Pathologic	Surgical-Pathologic
Stage 0	Histologic findings suspicious for malignancy, but not proven		
Stage I	Carcinoma confined to uterine corpus IA <sup>a</sup> : Length of uterine cavity is ≤8 cm IB <sup>a</sup> : Length of uterine cavity is >8 cm	IA: Tumor limited to endometrium IB: Invasion limited to less than half of myometrium IC: Invasion of half or greater of myometrium	Tumor confined to corpus uteri IA: No myometrial invasion or invasion to less than half of myometrium; endocervical glandular involvement only IB: Invasion of half or greater of myometrium
Stage II	Carcinoma involves uterine corpus and cervix	IIA: Endocervical glandular involvement only IIB: Cervical stromal invasion	Tumor invades cervical stroma but does not extend beyond uterus
Stage III	Carcinoma extends outside uterus but not outside pelvis	IIIA: Tumor invades serosa and/or adnexa and/or positive peritoneal cytology IIIB: Vaginal metastases IIIC: Metastases to pelvis and/or para-aortic lymph nodes	Local and/or regional spread of tumor IIIA: Tumor invades serosa of corpus uteri and/or adnexa IIIB: Vaginal and/or parametrial involvement IIIC1: Positive pelvic lymph nodes IIIC2: Positive para-aortic lymph nodes
Stage IV	Carcinoma extends outside the true pelvis or obviously invades mucosa of bladder or rectum	IVA: Tumor invasion of bladder and/or bowel mucosa IVB: Distant metastases including intra-abdominal and/or inguinal lymph nodes	IVA: Tumor invasion of bladder and/or bowel mucosa IVB: Distant metastases including intra-abdominal and/or inguinal lymph nodes
Histologic grade	Stage I tumors also subgrouped according to histologic type <sup>a</sup> : G1: Highly differentiated adenocarcinomas G2: Differentiated adenocarcinomas with partly solid areas G3: Predominately solid or entirely undifferentiated carcinomas	Stage is irrespective of grade G1: ≤5% of nonsquamous or nonmorular solid growth pattern G2: 6%–50% of nonsquamous or nonmorular solid growth pattern G3: >50% of nonsquamous or nonmorular solid growth pattern Notable nuclear atypia, inappropriate for architectural grade, raises the grade of a grade 1 or 2 tumor by 1	Stage is irrespective of grade G1: ≤5% of nonsquamous or nonmorular solid growth pattern G2: 6%–50% of nonsquamous or nonmorular solid growth pattern G3: >50% of nonsquamous or nonmorular solid growth pattern Notable nuclear atypia, inappropriate for architectural grade, raises the grade of a grade 1 or 2 tumor by 1

Abbreviation: FIGO, International Federation of Gynecology and Obstetrics.

<sup>a</sup>Modifications in 1971.Data from Boronow RC. Surgical staging of endometrial cancer: evolution, evaluation, and responsible challenge—a personal perspective. *Gynecol Oncol* 1997;66:179–189.

node metastases. Accurate staging, therefore, relies on comprehensive surgical staging to obtain specimens that can be thoroughly examined by pathologists for key prognostic factors, including myometrial invasion; cervical involvement; adnexal, peritoneal, and lymph node metastasis; histologic type and grade; and lymphovascular space involvement. Risk stratification systems incorporating pathologic prognostic factors are crucial in guiding clinical management decisions.<sup>5–7</sup>

Traditional and historical surgical staging of endometrial cancer involves removing the uterus, cervix, adnexa, and pelvic and para-aortic lymph nodes, and obtaining pelvic washings, followed by pathologic examination. This allows for an accurate diagnosis, identification of disease extent, prognostic

assessment, and selection of patients for adjuvant therapy. The advantage of surgical-pathologic staging over clinical staging was reported in the GOG 33 trial, which showed that 9% of patients with clinical stage I disease had pelvic nodal involvement, 6% had para-aortic lymphadenopathy, 5% had adnexal involvement, and 6% had other extrauterine metastases.<sup>8</sup> Comprehensive surgical staging also identifies patients with advanced-stage disease who require radiation therapy and/or chemotherapy; those with low-stage disease with high-risk features (high-grade tumors, deep myometrial invasion, lymphovascular space involvement) who should receive adjuvant treatment; and those without high-risk features who may safely be spared adjuvant chemoradiation and its attendant morbidity.<sup>8,9</sup>

Despite the benefits of a surgical-pathologic staging system, the 2009 International Federation of Gynecology and Obstetrics (FIGO) staging system has its limitations, particularly in the setting of corpus-confined carcinoma. Because the current staging scheme applies uniformly to all cases, irrespective of staging adequacy or tumor type, clinical outcomes are highly variable. For example, using the Memorial Sloan Kettering Cancer Center Endometrial Cancer Nomogram,<sup>10</sup> a 65-year-old woman with FIGO grade 1 endometrioid carcinoma, middle-third myometrial invasion, and a benign lymphadenectomy would have an estimated 5-year overall survival (OS) rate of 92%, whereas a 65-year-old woman with serous carcinoma, middle-third myometrial invasion, and no lymph node evaluation would have an estimated 5-year OS rate of only 64%. This observation prompted a proposal to amend the current FIGO staging scheme.<sup>11</sup>

Another controversy related to surgical staging in endometrial cancer is the role of para-aortic lymph node dissection. It has been shown that the rate of isolated para-aortic lymph node involvement in the absence of pelvic lymph node involvement is very low (<2%).<sup>12</sup> Patients with high-risk disease have a higher frequency of para-aortic lymph node involvement, suggesting that para-aortic lymphadenectomy should be performed as part of surgical staging in these patients.<sup>13</sup> However, a classification and regression tree analysis found that OS was predicted by FIGO stage and grade (a binary system of low- vs high-grade) but not by para-aortic lymph node status,<sup>14</sup> advocating for an approach with less extensive lymph node dissection.

### Sentinel Lymph Node Mapping

Approximately 6% to 23% of women with endometrial cancer who undergo pelvic lymphadenectomy develop long-term morbidity, such as lymphedema.<sup>15,16</sup> However, this is likely an underestimation, given that patient surveys have indicated leg lymphedema rates as high as 20% to 40%.<sup>16</sup> To reduce this morbidity and improve the detection of lymph node metastases, a sentinel lymph node (SLN) mapping approach to the management of endometrial cancer was introduced and has been incorporated as an option in the NCCN Clinical Practice Guidelines in Oncology (NCCN Guidelines) for Uterine Neoplasms since 2014.<sup>17</sup> The goal of SLN mapping is to initially target and assess the lymph nodes most

likely to be involved by metastatic cancer (ie, the sentinel, or first, nodes in the path of lymphatic flow away from the tumor), thereby limiting the extent of surgery and morbidity associated with extensive lymphadenectomy. This technique identifies SLNs in approximately 85% of patients, of whom 12% have positive SLNs.<sup>18</sup> Detailed pathologic examination of SLNs (ultrastaging), which includes the assessment of multiple sections using routine stains, as well as immunohistochemistry, for epithelial markers,<sup>19</sup> allows for the detection of low-volume metastases that can be missed with standard techniques.<sup>18,19</sup> SLN assessment also can refine surgical-pathologic stage; for example, in one study, SLN biopsy results upstaged 10% of patients with low-risk and 15% of those with intermediate-risk endometrial cancer,<sup>20</sup> with implications for adjuvant treatment planning.

### Challenges in the Pathologic Evaluation of Critical Prognostic Factors

Assignment of histotype is straightforward in most endometrial cancers, but can be exceedingly difficult in some high-grade tumors exhibiting morphologic ambiguity.<sup>21,22</sup> There are several risk-group stratification systems based on surgical-pathologic staging of endometrial cancer<sup>7,9,13,23–27</sup>; however, the poor reproducibility of histotype and grade classification<sup>21,22,28–30</sup> presents challenges for accurate prognostic assessment,<sup>27</sup> selecting optimal treatment, determining eligibility for clinical trials, and comparison of treatment interventions between studies. Integrating pathologic parameters with findings of molecular genetic analyses (described herein) may provide a more accurate and prognostically relevant classification of these tumors.<sup>31–34</sup>

Tumor grade and histotype designation in preoperative biopsy and curettage specimens may be incorrect.<sup>35</sup> For example, in one study, 1% of preoperative grade 1 endometrioid adenocarcinomas were upgraded to grade 2/3 cancers, and a further 1% harbored a high-risk histotype (serous or clear cell carcinoma) in the hysterectomy specimens.<sup>36</sup> Similarly, the undifferentiated component of a dedifferentiated carcinoma, which often lies deep to the well-differentiated component, may not be sampled in a biopsy or curettage specimen.<sup>37,38</sup> These sampling errors are more likely to occur with small-volume samples. In these cases, there is a potential for surgical understaging due to the failure to detect high-risk features

(high-grade tumor component) in the preoperative specimens.

Although SLN biopsy offers the advantages of accurate staging and reduced morbidity from avoidance of an unnecessary lymphadenectomy, its long-term survival benefits, if any, are unknown.<sup>3</sup> Furthermore, the clinical significance of small tumor volumes (eg, isolated tumor cells) in SLNs is unknown, and further studies with long-term follow-up are ongoing.

## Evolving Diagnostic Paradigms in Endometrial Cancer and Clinical Implications

### Molecular Genetic Findings and Integrated Pathologic-Genetic Classification

The Cancer Genome Atlas (TCGA) study of endometrioid and serous carcinomas found mutations in several genes (eg, *TP53*, *PTEN*, *PIK3CA*, *PPP2R1A*, *FBXW7*, *CTNNB1*, *KRAS*, and *POLE*) and, more importantly, identified 4 major genomically defined classes of tumor (*POLE*-ultramutated, microsatellite instability–hypermutated [MSI-H], copy-number-low, and copy-number-high). These groups were clinically significant, because they correlated with progression-free survival; patients with *POLE*-mutated tumors had an excellent prognosis and those with copy-number-high tumors had poor outcomes, whereas the MSI-H and copy-number-low groups had intermediate prognoses.<sup>34</sup> Recently, DNA ploidy was shown to differ between TCGA groups and was highest in the *p53*-aberrant group. Abnormal DNA ploidy was associated with higher grade, nonendometrioid histotype, and poorer survival (particularly in mismatch repair [MMR]–deficient tumors).<sup>39</sup> A recent study of endometrial clear cell carcinomas identified similar genomic classes, which were also associated with prognosis.<sup>40</sup> Uterine carcinosarcomas also frequently harbor mutations in *TP53*, *PTEN*, *PIK3CA*, *PPP2R1A*, *FBXW7*, and *KRAS*, similar to endometrioid and serous carcinomas.<sup>41</sup>

It is also apparent that genomic classes of endometrial carcinoma are associated with phenotypes. Copy-number-high tumors, which are characterized by *TP53* mutations and alterations associated with cell cycle deregulation, constitute some high-grade endometrioid adenocarcinomas and clear cell carcinomas, and all serous cancers.<sup>34,40</sup> Copy-number-low tumors are predominantly low-grade endometrioid adenocarcinomas.<sup>34</sup> *POLE*-mutated endometrial car-

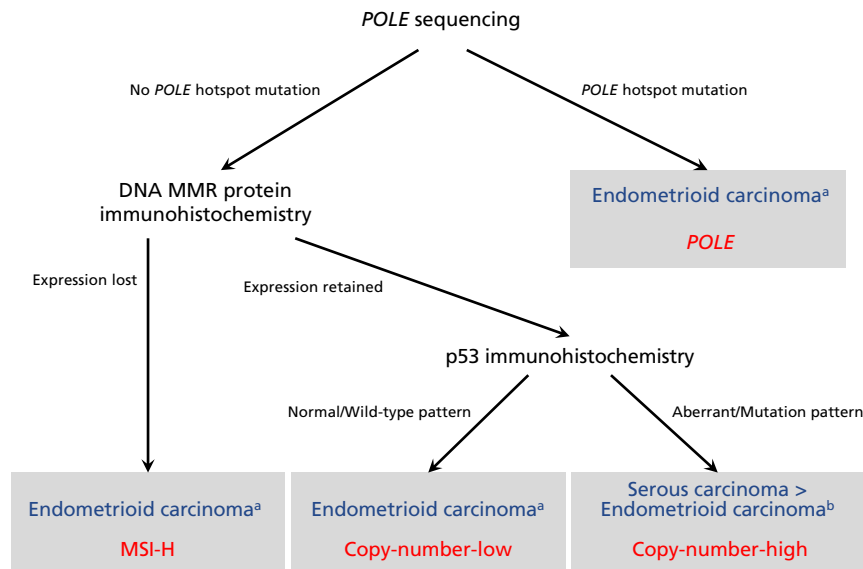
cinomas are typically characterized by high grade; tumor-infiltrating lymphocytes (TILs) and/or peritumoral lymphocytes; morphologic heterogeneity/ambiguity; and bizarre/giant tumor cell nuclei.<sup>42,43</sup> Endometrioid histotype is the most frequent, although *POLE* mutations have also been reported in clear cell carcinomas,<sup>40</sup> undifferentiated carcinomas,<sup>44</sup> and carcinosarcomas.<sup>45</sup> MSI-H endometrial cancers, which may be associated with germline alterations (Lynch syndrome) or sporadic aberrations, are associated with lower uterine segment location, endometrioid histology, mucinous differentiation, TILs, and peritumoral lymphocytes.<sup>46–49</sup>

Molecular classification of endometrial cancer has been shown to be reproducible and associated with clinical outcomes.<sup>31–34</sup> However, these algorithms do have some limitations. *p53* immunohistochemistry does not correlate perfectly with *TP53* copy number changes,<sup>39,40</sup> and its use in these algorithms may therefore misclassify some copy-number-high tumors. The algorithms do not address how to categorize tumors harboring more than one classifying genomic aberration (*POLE* mutations, MMR deficiency, or *TP53* mutations) when the algorithmic components are performed in parallel rather than sequentially. The algorithms do not allow for the exploration of the significant heterogeneity seen within the copy-number-low group.<sup>50,51</sup> Finally, in the ProMisE (Proactive Molecular Risk Classifier for Endometrial Cancer) algorithm, DNA MMR immunohistochemistry is performed before *POLE* sequencing, which may result in failure to detect MMR-deficient tumors with *POLE* mutations, as well as incorrectly classify these tumors as MMR-deficient rather than as *POLE*-mutated tumors; as a result, our approach differs slightly in performing *POLE* sequencing before DNA MMR immunohistochemistry (Figure 1).

Despite these limitations, an integrated genomic-pathologic classification scheme incorporating genomic-based classifications with traditional clinicopathologic prognostic parameters (Figure 1) represents the best available method for stratifying patients into prognostically distinct groups that may benefit from tailored treatment approaches.<sup>52</sup>

### Molecular Genetic Findings in Synchronous Endometrial and Ovarian Carcinomas

The staging of patients with synchronous endometrial and ovarian carcinomas traditionally has been



**Figure 1.** Diagnostic algorithm for integrated genomic-pathologic classification of endometrial carcinomas (blue represents histotype; red represents TCGA genomic class).

Abbreviations: MMR, mismatch repair; MSI-H, microsatellite instability–hypermutated; TCGA, The Cancer Genome Atlas.

<sup>a</sup>May also apply to clear cell carcinomas.

<sup>b</sup>This algorithm does not distinguish between histotypes of *TP53*-mutated copy-number-high tumors (ie, high-grade endometrioid carcinoma, serous carcinoma, and clear cell carcinoma).

based on pathologic criteria to determine whether the 2 tumors are independent primaries (each being low-stage disease) or whether 1 is a metastasis from the other (high-stage disease).<sup>53,54</sup> Two recent studies using massively parallel sequencing analyses showed that most synchronous endometrial and ovarian carcinomas are clonally related, and therefore, the latter scenario applies.<sup>55,56</sup> Nevertheless, many of these patients have excellent clinical outcomes belying their apparently high stage,<sup>57</sup> and further studies are required to determine the mechanisms underlying their indolent behavior.

### Recently Recognized Types and Variants of Endometrial Carcinoma

There are several recently described phenotypic variants of endometrial carcinoma, which may be associated with specific clinical phenotypes and genotype. A few examples are briefly presented.

#### Undifferentiated and Dedifferentiated Carcinoma:

Undifferentiated and dedifferentiated endometrial carcinomas are uncommon, highly aggressive tumors.<sup>38,58</sup> Undifferentiated carcinoma is a monomorphic tumor composed of small- to intermediate-sized cells arranged in sheets without any obvious epithelial differentiation, which mimics lymphoma, plasmacy-

toma, high-grade endometrial stromal sarcoma, or small cell carcinoma.<sup>38,58</sup> Approximately 40% of undifferentiated carcinomas are associated with a component of low-grade endometrioid adenocarcinoma; these cases are termed *dedifferentiated carcinomas*.<sup>37</sup>

Most undifferentiated carcinomas display immunohistochemical evidence of epithelial differentiation in the form of intense but focal epithelial membrane antigen and cytokeratin 18 expression, along with vimentin and CD138 expression.<sup>59,60</sup> Loss of expression of proteins involved in chromatin remodeling through SWI/SNF (SWItch/Sucrose Non-Fermentable) complexes, such as BRG-1 (the protein product of *SMARCA4*), INI-1 (protein product of *SMARCB1*), or BAF250a (protein product of *ARID1A*), may be seen.<sup>61,62</sup> DNA MMR deficiency and loss of expression of *MLH1* and *PMS2*, mostly due to *hMLH1* promoter methylation, is seen in 50% to 60% of tumors.<sup>63</sup> Genomically, these tumors harbor mutations in *POLE*, *SMARCA4*, *ARID1B*, *CTN-NB1*, *PPP2R1A*, or *TP53*.<sup>64</sup>

#### Corded and Hyalinized Endometrioid Carcinoma:

A subset of endometrioid adenocarcinomas (termed *corded and hyalinized endometrioid carcinomas* [CHECs]) show unusual morphologic features, including cords of epithelioid cells, spindle cells, and



a hyalinized stroma that sometimes form osteoid.<sup>65</sup> These tumors present mainly at a low stage and have a good prognosis. Identifying these tumors and distinguishing them from endometrial carcinosarcomas, which are usually seen in older patients and are highly aggressive malignancies, is important.<sup>41</sup> Awareness of CHEC allows for the ready morphologic distinction from carcinosarcoma, because the spindle cell component of CHEC lacks conspicuous atypia, in contrast to the high-grade appearance of the sarcomatous component of carcinosarcomas.

**Mesonephric-Like Carcinomas:** Mesonephric carcinomas have long been recognized in the uterine cervix. Recent studies have identified tumors involving the uterine corpus that show morphologic and immunohistochemical similarities to the cervical tumors. These uterine tumors are termed *mesonephric-like carcinomas*,<sup>66,67</sup> and display a uniform appearance, with tubular, solid and papillary architectural patterns, and are composed of cells with atypical, angulated and overlapping, vesicular nuclei. The tubular structures are small and may contain dense luminal eosinophilic material.<sup>66,67</sup> Immunohistochemically, the tumors express thyroid transcription factor 1 (TTF-1), as well as CD10, calretinin, and GATA-binding protein 3 (GATA3), whereas estrogen (ER) and progesterone receptors are negative.<sup>67</sup> Mutations in *KRAS*, *NRAS*, and chromatin remodeling genes (*ARID1A*, *ARID1B*, *SMARCA4*) have been reported in mesonephric carcinomas.<sup>68</sup>

### Biomarkers for Classification and Prognostic Assessment

**Identification of Molecular-Prognostic Subgroups:** MSI-H endometrial carcinomas can be effectively identified by assessing morphologic features (described earlier) and DNA MMR deficiencies in histologic material using immunohistochemistry with antibodies directed against MLH1, PMS2, MSH2, and MSH6.<sup>69,70</sup> There is a high level of concordance between the results of immunohistochemistry and PCR-based MSI analysis.<sup>71</sup> Immunohistochemical expression of p53 (classified as aberrant if absent or diffusely overexpressed) is associated with a poor prognosis in endometrial cancer<sup>72,73</sup> and correlates with *TP53* mutation status.<sup>74</sup> Identification of a *POLE* mutation in patients with endometrial cancer (based on morphologic features of the tumor and

*POLE* sequencing) may help these patients avoid overtreatment given their excellent prognosis.<sup>34</sup> *POLE*-mutated and MSI-H tumors are also amenable to immunotherapy (as discussed later).

Simplified diagnostic algorithms for the molecular classification of endometrial cancers into TCGA classes were recently proposed.<sup>50,75</sup> The ProMisE algorithm involves immunohistochemistry for DNA MMR proteins, sequencing of MMR-proficient tumors for *POLE* mutations, and immunohistochemistry for p53 in *POLE* wild-type tumors. This algorithm accurately classifies endometrial cancers as MMR-deficient (MSI-H), *POLE*-mutated, *TP53* wild-type (copy-number-low), or *TP53*-aberrant (copy-number-high),<sup>75</sup> and has potential as a prognostic and risk stratification assay for clinical use.

**High-Grade Endometrial Cancers:** The copy-number-high group of endometrial carcinomas identified in the TCGA study includes high-grade endometrioid adenocarcinomas and serous carcinomas. The histopathologic and immunohistochemical features of these tumors may overlap considerably, leading to poor interobserver reproducibility in the histotyping of high-grade endometrial carcinomas.<sup>22,30</sup> This poor reproducibility doubtless contributes to variability in the reported prognosis of patients with high-grade endometrioid adenocarcinoma compared with those with serous carcinoma.<sup>76–80</sup>

However, a recent study of copy-number-high endometrial carcinomas showed significant differences between high-grade endometrioid adenocarcinomas and serous carcinomas with respect to their stage distributions and sites of recurrence.<sup>81</sup> If these differences also correlate with other differences in clinical behavior, it is important to attempt to distinguish high-grade endometrioid adenocarcinomas from serous carcinomas using available biomarkers to supplement histopathologic interpretation. No single marker is absolutely diagnostic of either histotype, and therefore a panel of markers, including at least p53 and p16 with either ER or PTEN is recommended. Tumors that are p16-negative/PTEN-negative and/or *ARID1A*-negative/p16-negative/p53 wild-type are most likely endometrioid, whereas serous carcinomas are more likely to be p53-aberrant/p16-positive/ER-negative.<sup>82</sup> Tumors with discordant findings may be subjected to an expanded immunohistochemical panel that includes DNA MMR proteins (MLH1, PMS2, MSH2, MSH6), and loss of expression of at least one

of these would support the diagnosis of endometrioid adenocarcinoma.

**CTNNB1-Mutated Endometrial Carcinomas:** Patients with low-stage endometrial cancer without high-risk features, as described earlier, generally have excellent outcomes; however, a small proportion of these patients do poorly. A recent study exploring factors associated with poor outcomes in women with low-grade, early-stage endometrial carcinomas found that in patients with endometrioid adenocarcinomas, *CTNNB1* mutations were found to be independent predictors of poorer recurrence-free survival.<sup>83</sup> In this study, 84% of tumors with *CTNNB1* mutations showed nuclear expression of beta catenin (the protein product of *CTNNB1*) by immunohistochemistry.<sup>83</sup>

### Pathology and Precision Medicine in Endometrial Cancer

Pathologists play an important role in the development and implementation of novel therapies targeting molecular/genomic alterations in endometrial cancer. Roles of pathology in the present era of precision oncology include identification of homogenous subsets of tumors, which are critical to obtain meaningful results from exploratory molecular/genomic studies seeking to identify novel targets; evaluation of molecular biomarker expression and their localization at the tissue level, which can assist in treatment decisions; phenotype-genotype correlations that help identify tumors likely to harbor specific molecular targets or likely to be amenable to specific therapy; and selection of suitable patients, based on their phenotypes and biomarker profiles, for entry into clinical trials of novel therapies.

**Identification of Candidates for Immunotherapy:** *POLE*-mutated and MMR-deficient tumors exhibit TILs, high levels of neoantigens, and expression of

immune checkpoint regulators, such as programmed death receptor-1 (PD-1)<sup>84,85</sup> or its ligand, PD-L1,<sup>86</sup> which are thought to promote escape from immune surveillance. Immune checkpoint blockade with the anti-PD1 antibody pembrolizumab has shown responses in patients with *POLE*-mutated<sup>85</sup> and MMR-deficient endometrial cancer,<sup>87</sup> and pembrolizumab has been FDA-approved for metastatic cancers exhibiting MMR deficiency. PD-L1 expression can be directly examined in tissues using immunohistochemistry, but the optimal methods and antibodies have yet to be standardized.<sup>88</sup>

**Identification of Candidates for MAPK Pathway Inhibition:** *KRAS* mutations are common in endometrial cancer<sup>34</sup> and are associated with mucinous differentiation.<sup>89</sup> *ERBB2* amplifications are also identified in endometrial serous carcinomas.<sup>90</sup> *KRAS* is not a direct molecular therapeutic target, but the identification of tumors with MAPK pathway activation might be susceptible to therapy directed against other components of the MAPK/ERK pathway, such as members of the epidermal growth factor receptor family.

### Conclusions

During the past 2 decades, numerous *ex vivo*, genomic, translational, pathologic, and clinical studies have significantly expanded the understanding of endometrial cancer. This improved understanding has led to refinements in the approach to the diagnosis and treatment of women with these tumors. As an integral part of any multidisciplinary team, pathology continues to play an important role in diagnosis and prognostic assessment, risk stratification and therapeutic decision-making, and the development and implementation of novel therapeutic agents and strategies for women with these cancers.

### References

1. Siegel RL, Miller KD, Jemal A. Cancer Statistics, 2017. *CA Cancer J Clin* 2017;67:7–30.
2. Dijkhuizen FP, Mol BW, Brolmann HA, Heintz AP. The accuracy of endometrial sampling in the diagnosis of patients with endometrial carcinoma and hyperplasia: a meta-analysis. *Cancer* 2000;89:1765–1772.
3. SGO Clinical Practice Endometrial Cancer Working Group, Burke WM, Orr J, et al. Endometrial cancer: a review and current management strategies: part I. *Gynecol Oncol* 2014;134:385–392.
4. Boronow RC. Surgical staging of endometrial cancer: evolution, evaluation, and responsible challenge—a personal perspective. *Gynecol Oncol* 1997;66:179–189.
5. Abu-Rustum NR, Zhou Q, Gomez JD, et al. A nomogram for predicting overall survival of women with endometrial cancer following primary therapy: toward improving individualized cancer care. *Gynecol Oncol* 2010;116:399–403.
6. Bendifallah S, Canlorbe G, Raimond E, et al. A clue towards improving the European Society of Medical Oncology risk group classification in apparent early stage endometrial cancer? Impact of lymphovascular space invasion. *Br J Cancer* 2014;110:2640–2646.

7. Kong TW, Chang SJ, Paek J, et al. Risk group criteria for tailoring adjuvant treatment in patients with endometrial cancer: a validation study of the Gynecologic Oncology Group criteria. *J Gynecol Oncol* 2015;26:32–39.
8. Creasman WT, Morrow CP, Bundy BN, et al. Surgical pathologic spread patterns of endometrial cancer. A Gynecologic Oncology Group study. *Cancer* 1987;60(8 Suppl):2035–2041.
9. Keys HM, Roberts JA, Brunetto VL, et al. A phase III trial of surgery with or without adjunctive external pelvic radiation therapy in intermediate risk endometrial adenocarcinoma: a Gynecologic Oncology Group study. *Gynecol Oncol* 2004;92:744–751.
10. Endometrial Cancer Nomogram. Memorial Sloan Kettering Cancer Center Web site. Available at: <https://www.mskcc.org/nomograms/endometrial>. Accessed October 1, 2017.
11. Barlin JN, Soslow RA, Lutz M, et al. Redefining stage I endometrial cancer: incorporating histology, a binary grading system, myometrial invasion, and lymph node assessment. *Int J Gynecol Cancer* 2013;23:1620–1628.
12. Abu-Rustum NR, Gomez JD, Alektiar KM, et al. The incidence of isolated paraaortic nodal metastasis in surgically staged endometrial cancer patients with negative pelvic lymph nodes. *Gynecol Oncol* 2009;115:236–238.
13. Mariani A, Dowdy SC, Cliby WA, et al. Prospective assessment of lymphatic dissemination in endometrial cancer: a paradigm shift in surgical staging. *Gynecol Oncol* 2008;109:11–18.
14. Barlin JN, Zhou Q, St Clair CM, et al. Classification and regression tree (CART) analysis of endometrial carcinoma: seeing the forest for the trees. *Gynecol Oncol* 2013;130:452–456.
15. Abu-Rustum NR, Alektiar K, Iasonos A, et al. The incidence of symptomatic lower-extremity lymphedema following treatment of uterine corpus malignancies: a 12-year experience at Memorial Sloan-Kettering Cancer Center. *Gynecol Oncol* 2006;103:714–718.
16. Yost KJ, Cheville AL, Al-Hilli MM, et al. Lymphedema after surgery for endometrial cancer: prevalence, risk factors, and quality of life. *Obstet Gynecol* 2014;124(2 Pt 1):307–315.
17. Koh WJ, Abu-Rustum NR, Bean S, et al. NCCN Clinical Practice Guidelines in Oncology: Uterine Neoplasms. Version 1.2018. Accessed January 2, 2018. To view the most recent version of these guidelines, visit [NCCN.org](http://NCCN.org).
18. Khoury-Collado F, St Clair C, Abu-Rustum NR. Sentinel lymph node mapping in endometrial cancer: an update. *Oncologist* 2016;21:461–466.
19. Kim CH, Soslow RA, Park KJ, et al. Pathologic ultrastaging improves micrometastasis detection in sentinel lymph nodes during endometrial cancer staging. *Int J Gynecol Cancer* 2013;23:964–970.
20. Ballester M, Dubernard G, Lecuru F, et al. Detection rate and diagnostic accuracy of sentinel-node biopsy in early stage endometrial cancer: a prospective multicentre study (SENTI-ENDO). *Lancet Oncol* 2011;12:469–476.
21. Soslow RA. Endometrial carcinomas with ambiguous features. *Semin Diagn Pathol* 2010;27:261–273.
22. Gilks CB, Oliva E, Soslow RA. Poor interobserver reproducibility in the diagnosis of high-grade endometrial carcinoma. *Am J Surg Pathol* 2013;37:874–881.
23. Creutzberg CL, van Putten WL, Koper PC, et al. Surgery and postoperative radiotherapy versus surgery alone for patients with stage-I endometrial carcinoma: multicentre randomised trial. PORTEC Study Group. *Post Operative Radiation Therapy in Endometrial Carcinoma*. *Lancet* 2000;355:1404–1411.
24. Kwon JS, Qiu F, Saskin R, Carey MS. Are uterine risk factors more important than nodal status in predicting survival in endometrial cancer? *Obstet Gynecol* 2009;114:736–743.
25. Colombo N, Preti E, Landoni F, et al. Endometrial cancer: ESMO clinical practice guidelines for diagnosis, treatment and follow-up. *Ann Oncol* 2013;24(Suppl 6):vi33–38.
26. AlHilli MM, Mariani A, Bakkum-Gamez JN, et al. Risk-scoring models for individualized prediction of overall survival in low-grade and high-grade endometrial cancer. *Gynecol Oncol* 2014;133:485–493.
27. Bendifallah S, Canlorbe G, Collinet P, et al. Just how accurate are the major risk stratification systems for early-stage endometrial cancer? *Br J Cancer* 2015;112:793–801.
28. Guan H, Semaan A, Bandyopadhyay S, et al. Prognosis and reproducibility of new and existing binary grading systems for endometrial carcinoma compared to FIGO grading in hysterectomy specimens. *Int J Gynecol Cancer* 2011;21:654–660.
29. Han G, Sidhu D, Duggan MA, et al. Reproducibility of histological cell type in high-grade endometrial carcinoma. *Mod Pathol* 2013;26:1594–1604.
30. Hoang LN, McConechy MK, Kobel M, et al. Histotype-genotype correlation in 36 high-grade endometrial carcinomas. *Am J Surg Pathol* 2013;37:1421–1432.
31. Salvesen HB, Carter SL, Mannelqvist M, et al. Integrated genomic profiling of endometrial carcinoma associates aggressive tumors with indicators of PI3 kinase activation. *Proc Natl Acad Sci U S A* 2009;106:4834–4839.
32. Le Gallo M, O'Hara AJ, Rudd ML, et al. Exome sequencing of serous endometrial tumors identifies recurrent somatic mutations in chromatin-remodeling and ubiquitin ligase complex genes. *Nat Genet* 2012;44:1310–1315.
33. McConechy MK, Ding J, Cheang MC, et al. Use of mutation profiles to refine the classification of endometrial carcinomas. *J Pathol* 2012;228:20–30.
34. Kandath C, Schultz N, Cherniack AD, et al. Integrated genomic characterization of endometrial carcinoma. *Nature* 2013;497:67–73.
35. Mitchard J, Hirschowitz L. Concordance of FIGO grade of endometrial adenocarcinomas in biopsy and hysterectomy specimens. *Histopathology* 2003;42:372–378.
36. Leitao MM Jr, Kehoe S, Barakat RR, et al. Comparison of D&C and office endometrial biopsy accuracy in patients with FIGO grade I endometrial adenocarcinoma. *Gynecol Oncol* 2009;113:105–108.
37. Giordano G, D'Adda T, Bottarelli L, et al. Two cases of low-grade endometrioid carcinoma associated with undifferentiated carcinoma of the uterus (dedifferentiated carcinoma): a molecular study. *Pathol Oncol Res* 2012;18:523–528.
38. Tafe LJ, Garg K, Chew I, et al. Endometrial and ovarian carcinomas with undifferentiated components: clinically aggressive and frequently underrecognized neoplasms. *Mod Pathol* 2010;23:781–789.
39. Proctor L, Pradhan M, Leung S, et al. Assessment of DNA ploidy in the ProMisE molecular subgroups of endometrial cancer. *Gynecol Oncol* 2017;146:596–602.
40. DeLair DF, Burke KA, Selenica P, et al. The genetic landscape of endometrial clear cell carcinomas. *J Pathol* 2017;243:230–241.
41. Cherniack AD, Shen H, Walter V, et al. Integrated molecular characterization of uterine carcinosarcoma. *Cancer Cell* 2017;31:411–423.
42. Hussein YR, Weigelt B, Levine DA, et al. Clinicopathological analysis of endometrial carcinomas harboring somatic POLE exonuclease domain mutations. *Mod Pathol* 2015;28:505–514.
43. Bakhsh S, Kinloch M, Hoang LN, et al. Histopathological features of endometrial carcinomas associated with POLE mutations: implications for decisions about adjuvant therapy. *Histopathology* 2016;68:916–924.
44. Kobel M, Hoang LN, Tessier-Cloutier B, et al. Undifferentiated endometrial carcinomas show frequent loss of core switch/sucrose nonfermentable complex proteins. *Am J Surg Pathol* 2017;42:76–83.
45. Hoang LN, Kinloch MA, Leo JM, et al. Interobserver agreement in endometrial carcinoma histotype diagnosis varies depending on The Cancer Genome Atlas (TCGA)-based molecular subgroup. *Am J Surg Pathol* 2017;41:245–252.
46. Broaddus RR, Lynch HT, Chen LM, et al. Pathologic features of endometrial carcinoma associated with HNPCC: a comparison with sporadic endometrial carcinoma. *Cancer* 2006;106:87–94.
47. Shia J, Black D, Hummer AJ, et al. Routinely assessed morphological features correlate with microsatellite instability status in endometrial cancer. *Hum Pathol* 2008;39:116–125.
48. Rabban JT, Calkins SM, Karnezis AN, et al. Association of tumor morphology with mismatch-repair protein status in older endometrial cancer patients: implications for universal versus selective screening strategies for Lynch syndrome. *Am J Surg Pathol* 2014;38:793–800.
49. Sloan EA, Moskaluk CA, Mills AM. Mucinosa differentiation with tumor infiltrating lymphocytes is a feature of sporadically methylated endometrial carcinomas. *Int J Gynecol Pathol* 2017;36:205–216.
50. Stelloo E, Nout RA, Osse EM, et al. Improved risk assessment by integrating molecular and clinicopathological factors in early-stage endometrial cancer-combined analysis of the PORTEC cohorts. *Clin Cancer Res* 2016;22:4215–4224.
51. Cancer Genome Atlas Research Network, Kandath C, Schultz N, et al. Integrated genomic characterization of endometrial carcinoma. *Nature* 2013;497:67–73.
52. Murali R, Soslow RA, Weigelt B. Classification of endometrial carcinoma: more than two types. *Lancet Oncol* 2014;15:e268–278.
53. Ulbright TM, Roth LM. Metastatic and independent cancers of the endometrium and ovary: a clinicopathologic study of 34 cases. *Hum Pathol* 1985;16:28–34.



## Pathology and Genomics in Endometrial Cancer

54. Nishimura N, Hachisuga T, Yokoyama M, et al. Clinicopathologic analysis of the prognostic factors in women with coexistence of endometrioid adenocarcinoma in the endometrium and ovary. *J Obstet Gynaecol Res* 2005;31:120–126.
55. Schultheis AM, Ng CK, De Filippo MR, et al. Massively parallel sequencing-based clonality analysis of synchronous endometrioid endometrial and ovarian carcinomas. *J Natl Cancer Inst* 2016;108:djv427.
56. Anglesio MS, Wang YK, Maassen M, et al. Synchronous endometrial and ovarian carcinomas: evidence of clonality. *J Natl Cancer Inst* 2016;108:djv428.
57. Williams MG, Bandera EV, Demissie K, Rodriguez-Rodriguez L. Synchronous primary ovarian and endometrial cancers: a population-based assessment of survival. *Obstet Gynecol* 2009;113:783–789.
58. Altrabulsi B, Malpica A, Deavers MT, et al. Undifferentiated carcinoma of the endometrium. *Am J Surg Pathol* 2005;29:1316–1321.
59. Li Z, Zhao C. Clinicopathologic and immunohistochemical characterization of dedifferentiated endometrioid adenocarcinoma. *Appl Immunohistochem Mol Morphol* 2016;24:562–568.
60. Ramalingam P, Masand RP, Euscher ED, Malpica A. Undifferentiated carcinoma of the endometrium: an expanded immunohistochemical analysis including PAX-8 and basal-like carcinoma surrogate markers. *Int J Gynecol Pathol* 2016;35:410–418.
61. Stewart CJ, Crook ML. SWI/SNF complex deficiency and mismatch repair protein expression in undifferentiated and dedifferentiated endometrial carcinoma. *Pathology* 2015;47:439–445.
62. Strehl JD, Wachter DL, Fiedler J, et al. Pattern of SMARCB1 (INI1) and SMARCA4 (BRG1) in poorly differentiated endometrioid adenocarcinoma of the uterus: analysis of a series with emphasis on a novel SMARCA4-deficient dedifferentiated rhabdoid variant. *Ann Diagn Pathol* 2015;19:198–202.
63. Garg K, Leitao MM Jr, Kauff ND, et al. Selection of endometrial carcinomas for DNA mismatch repair protein immunohistochemistry using patient age and tumor morphology enhances detection of mismatch repair abnormalities. *Am J Surg Pathol* 2009;33:925–933.
64. Kuhn E, Ayhan A, Bahadiri-Talbot A, et al. Molecular characterization of undifferentiated carcinoma associated with endometrioid carcinoma. *Am J Surg Pathol* 2014;38:660–665.
65. Murray SK, Clement PB, Young RH. Endometrioid carcinomas of the uterine corpus with sex cord-like formations, hyalinization, and other unusual morphologic features: a report of 31 cases of a neoplasm that may be confused with carcinosarcoma and other uterine neoplasms. *Am J Surg Pathol* 2005;29:157–166.
66. Kenny SL, McBride HA, Jamison J, McCluggage WG. Mesonephric adenocarcinomas of the uterine cervix and corpus: HPV-negative neoplasms that are commonly PAX8, CA125, and HMG A2 positive and that may be immunoreactive with TTF1 and hepatocyte nuclear factor 1-beta. *Am J Surg Pathol* 2012;36:799–807.
67. McFarland M, Quick CM, McCluggage WG. Hormone receptor-negative, thyroid transcription factor 1-positive uterine and ovarian adenocarcinomas: report of a series of mesonephric-like adenocarcinomas. *Histopathology* 2016;68:1013–1020.
68. Mirkovic J, Sholl LM, Garcia E, et al. Targeted genomic profiling reveals recurrent KRAS mutations and gain of chromosome 1q in mesonephric carcinomas of the female genital tract. *Mod Pathol* 2015;28:1504–1514.
69. de Leeuw WJ, Dierssen J, Vasen HF, et al. Prediction of a mismatch repair gene defect by microsatellite instability and immunohistochemical analysis in endometrial tumours from HNPCC patients. *J Pathol* 2000;192:328–335.
70. Peterson LM, Kipp BR, Halling KC, et al. Molecular characterization of endometrial cancer: a correlative study assessing microsatellite instability, MLH1 hypermethylation, DNA mismatch repair protein expression, and PTEN, PIK3CA, KRAS, and BRAF mutation analysis. *Int J Gynecol Pathol* 2012;31:195–205.
71. McConechy MK, Talhouk A, Li-Chang HH, et al. Detection of DNA mismatch repair (MMR) deficiencies by immunohistochemistry can effectively diagnose the microsatellite instability (MSI) phenotype in endometrial carcinomas. *Gynecol Oncol* 2015;137:306–310.
72. Alkushi A, Lim P, Coldman A, et al. Interpretation of p53 immunoreactivity in endometrial carcinoma: establishing a clinically relevant cut-off level. *Int J Gynecol Pathol* 2004;23:129–137.
73. Talhouk A, McConechy MK, Leung S, et al. A clinically applicable molecular-based classification for endometrial cancers. *Br J Cancer* 2015;113:299–310.
74. Lax SF, Kendall B, Tashiro H, et al. The frequency of p53, K-ras mutations, and microsatellite instability differs in uterine endometrioid and serous carcinoma: evidence of distinct molecular genetic pathways. *Cancer* 2000;88:814–824.
75. Talhouk A, Hoang LN, McConechy MK, et al. Molecular classification of endometrial carcinoma on diagnostic specimens is highly concordant with final hysterectomy: earlier prognostic information to guide treatment. *Gynecol Oncol* 2016;143:46–53.
76. Altman AD, Ferguson SE, Atenafu EG, et al. Canadian High Risk Endometrial Cancer (CHREC) consortium: analyzing the clinical behavior of high risk endometrial cancers. *Gynecol Oncol* 2015;139:268–274.
77. Alkushi A, Kobel M, Kalloger SE, Gilks CB. High-grade endometrial carcinoma: serous and grade 3 endometrioid carcinomas have different immunophenotypes and outcomes. *Int J Gynecol Pathol* 2010;29:343–350.
78. Voss MA, Ganesan R, Ludeman L, et al. Should grade 3 endometrioid endometrial carcinoma be considered a type 2 cancer—a clinical and pathological evaluation. *Gynecol Oncol* 2012;124:15–20.
79. Soslow RA, Bissonnette JP, Wilton A, et al. Clinicopathologic analysis of 187 high-grade endometrial carcinomas of different histologic subtypes: similar outcomes belie distinctive biologic differences. *Am J Surg Pathol* 2007;31:979–987.
80. Ayeni TA, Bakkum-Gamez JN, Mariani A, et al. Comparative outcomes assessment of uterine grade 3 endometrioid, serous, and clear cell carcinomas. *Gynecol Oncol* 2013;129:478–485.
81. Bosse T, Nout RA, McAlpine JN, et al. Molecular classification of grade 3 endometrioid endometrial cancers identifies distinct prognostic subgroups. *Am J Surg Pathol*, in press.
82. Chen W, Husain A, Nelson GS, et al. Immunohistochemical profiling of endometrial serous carcinoma. *Int J Gynecol Pathol* 2017;36:128–139.
83. Kurnit KC, Kim GN, Fellman BM, et al. CTNNB1 (beta-catenin) mutation identifies low grade, early stage endometrial cancer patients at increased risk of recurrence. *Mod Pathol* 2017;30:1032–1041.
84. Howitt BE, Shukla SA, Sholl LM, et al. Association of polymerase e-mutated and microsatellite-instable endometrial cancers with neoantigen load, number of tumor-infiltrating lymphocytes, and expression of PD-1 and PD-L1. *JAMA Oncol* 2015;1:1319–1323.
85. Mehnert JM, Panda A, Zhong H, et al. Immune activation and response to pembrolizumab in POLE-mutant endometrial cancer. *J Clin Invest* 2016;126:2334–2340.
86. Gatalica Z, Snyder C, Maney T, et al. Programmed cell death 1 (PD-1) and its ligand (PD-L1) in common cancers and their correlation with molecular cancer type. *Cancer Epidemiol Biomarkers Prev* 2014;23:2965–2970.
87. Le DT, Durham JN, Smith KN, et al. Mismatch repair deficiency predicts response of solid tumors to PD-1 blockade. *Science* 2017;357:409–413.
88. Sholl LM, Aisner DL, Allen TC, et al. Programmed death ligand-1 immunohistochemistry—a new challenge for pathologists: a perspective from members of the Pulmonary Pathology Society. *Arch Pathol Lab Med* 2016;140:341–344.
89. Xiong J, He M, Jackson C, et al. Endometrial carcinomas with significant mucinous differentiation associated with higher frequency of k-ras mutations: a morphologic and molecular correlation study. *Int J Gynecol Cancer* 2013;23:1231–1236.
90. Buza N, Hui P. Marked heterogeneity of HER2/NEU gene amplification in endometrial serous carcinoma. *Genes Chromosomes Cancer* 2013;52:1178–1186.